

The suppressive effects of simvastatin on fertility impairment induced by experimental unilateral testicular ischemia-reperfusion in mice

Ali Shalizar Jalali^{1,*}, Mehdi Behfar², Gholamreza Najafi¹, Alireza Nourian¹, Mehdi Shahkarimi¹, Mobin Koohestani¹

¹Department of Basic Sciences, Faculty of Veterinary Medicine, Urmia University, Urmia, Iran.

²Department of Surgery and Diagnostic Imaging, Faculty of Veterinary Medicine, Urmia University, Urmia, Iran.

Received: 21 Oct 2016

Accepted: 7 Dec 2016

Abstract

Background: The basic pathophysiologic phenomenon in testicular torsion, a common urologic emergency, is ischemia followed by reperfusion. In this study, we evaluated the effect(s) of simvastatin (SIM), a lipid lowering agent with antioxidant and anti-inflammatory properties, on mouse epididymal sperm fertilizing potential and the subsequent in vitro embryo development in experimentally-induced unilateral testicular ischemia-reperfusion (IR).

Methods: Adult male mice were divided into four groups (n = 6, each). Following anaesthesia, IR was induced by clamping the left testicular vessels with an atraumatic microvascular clamp for 30 minutes in the IR group. In IR+SIM group, in addition, the mice received SIM (20 mg/kg per day) orally for 3 days starting from the day of induction of the experimental IR. A vehicle-treated control group and a SIM-only treated group were also included. Ipsilateral and contralateral epididymal sperms fertilizing capacity was analyzed in four groups after 35 days.

Results: Significant reduction in fertilization as well as blastulation rates were observed in the IR group. However, the SIM treatment considerably attenuated the IR-induced negative alterations in the above-mentioned parameters.

Conclusion: These findings revealed the repro-protective effects of SIM on the murine model of IR through the inhibition of oxidative injuries and inflammatory reactions.

Keywords: Ischemia-reperfusion, Simvastatin, Fertilization, Blastocyst, Mice

Introduction

Testicular torsion is a common pediatric urologic emergency with the incidence of one in 25000 males above the age of 25 (1). It mainly occurs due to the congenital malformation of vaginal process; however, 4 to 8 percent of torsion cases are associated with traumas (2). Spermatogenic disorders, altered sex hormone levels, and subfertility are the main outcomes

of the delayed diagnosis and/or the misdiagnosis of testicular torsion (3). It has been reported that the twisted spermatic cord could lead to blood supply blockage and eventually testicular ischemia (4). It has also been reported that blood reperfusion followed by surgical detorsion can result in germ cell apoptosis and spermatogenesis disruption through reactive oxygen species (ROS) over-generation and neutrophil infiltration (5).

*Corresponding author: Dr. Ali Shalizar Jalali, Histology and Embryology Research Laboratories, Department of Basic Sciences, Faculty of Veterinary Medicine, Urmia University, Urmia, Iran, **Telefax:** +98-44-32771926, **Email:** ali_shalizar@yahoo.com

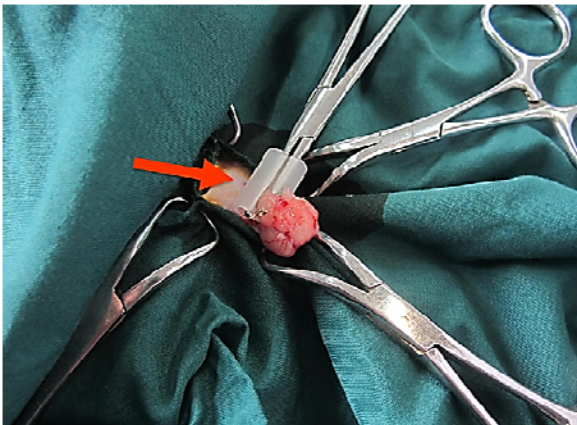


Fig 1. The experimental unilateral testicular ischemia-reperfusion (IR) in mice. The arrow indicates the left testicular vessels clamping in order to induce IR.

Statins, as 3-hydroxy 3-methylglutaryl coenzyme A reductase inhibitors, are the first-line cholesterol-lowering agents with pleiotropic effects, including antioxidant and anti-inflammatory properties (6). Simvastatin (SIM) is a potent antioxidant and an anti-inflammatory drug of statin series. It is worth noting that the considerable protective effects of Simvastatin against ischemia-reperfusion (IR)-induced injuries on various organs such as heart, lung, liver, kidney and intestine have previously been shown (7).

Based on this concept, this study was designed to examine the possible protective effects of SIM against the experimental unilateral testicular IR-evoked disturbance in mouse epididymal sperm fertilizing capacity and the subsequent *in vitro* embryo development.

Materials and Methods

Twenty-four adult male mice were obtained from the Animal Production Center of the Faculty of Veterinary Medicine, Urmia University, Urmia, Iran, and were housed under standard housing conditions of 25 ± 2 °C, the relative humidity of $50 \pm 10\%$, and the photo period of 12 h dark/12 h light. The food and water were available *ad libitum*. The study was carried out in accordance with the guidelines for the care and use of laboratory animals and the experimental protocol was approved by the Research Ethics Committee (Faculty of Veterinary Medicine, Urmia University, Urmia, Iran).

Experimental Protocol

After acclimatization for one week, the mice were randomly categorized into four groups of six mice each including control, SIM, IR and IR + SIM groups. The control mice received normal saline (0.1 ml/day; PO) for three days. Simvastatin was administered orally to animals at a dose of 20 mg/kg per day (8) for three days in the SIM group. In the IR group, mice were undergone experimental unilateral testicular IR. In IR + SIM group, mice received SIM (20 mg/kg per day) orally for 3 days starting from the day of induction of experimental unilateral testicular IR.

Surgical Procedure

In order to induce experimental unilateral testicular IR (Fig 1), following anesthesia (ketamine (40 mg/kg) + xylazine (5 mg/kg)), the left testis was exteriorized through a midline incision and testicular vessels were clamped with an atraumatic microvascular clamp for 30 minutes (9, 10).

Sampling

All animals in the four experimental groups were euthanized with ketamine after 35 days, and the epididymides were cautiously dissected out and cleaned from the adhering connective tissue under a 20-time magnification provided by a stereo zoom microscope.

Epididymal sperm fertilizing potential and early embryo development analyses

In order to provide oocytes for fertilization capacity test, the female mice were superovulated via the intraperitoneal injection of 7.50 IU pregnant mare's serum gonadotropin (PMSG, Folligon, Netherlands), which was followed by the intraperitoneal injection of 7.50 IU human chorionic gonadotropin (hCG, Folligon, Netherlands) 48 hours later (11). Fourteen hours after hCG administration, the female mice were euthanized, their oviducts were removed and each ampullar portion was placed into a plastic dish containing HTF medium. The ovulated oocytes were collected from the ampullar portions using dissecting technique under a stereo zoom microscope. Ten to 15 μ l of capacitated sperm suspension was added to the fertilization medium (for each animal, a total of 20 oocytes were divided into 10 fertilization drops) and six hours later, the fertilization rate was determined by the observation of male and female pronuclei using an inverted microscope. Moreover, the blastulation rate was evaluated by

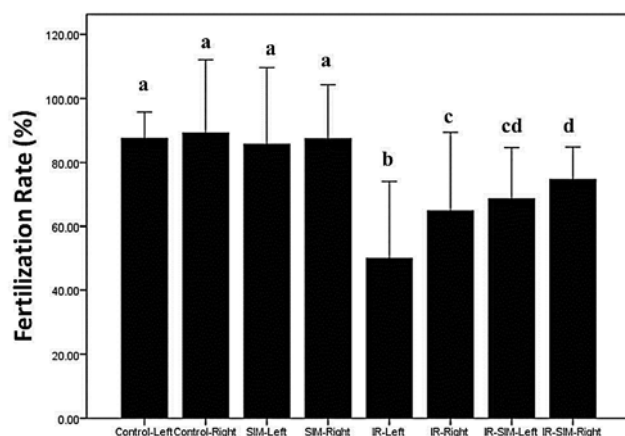


Fig 2. The bilateral effects of unilateral testicular ischemia-reperfusion on epididymal sperms fertilizing potential in all experimental groups. Different superscripts denote statistical difference at a $p < 0.05$. SIM: Simvastatin; IR: Ischemia-reperfusion

recording the number of embryos that had reached the blastocyst development stage (12).

Statistical analysis

All data were expressed as mean \pm standard error of mean (SEM) and analyzed using SPSS 18.0 software. The differences among the experimental groups were analyzed by one-way ANOVA, followed by Tukey post-hoc test. The p -values < 0.05 were considered significant.

Results

The Epididymal sperms in vitro fertilizing potentials in all the experimental groups are shown in figure 2. The IR caused a significant reduction in ipsilateral and contralateral epididymal sperms fertilizing ability compared to those of the control and SIM-only groups. The administration of SIM significantly increased the fertilization rates of ipsilateral and the contralateral epididymal spermatozoa compared to those of the IR group. Further, the left epididymal sperms fertilizing capacity was significantly lower than that of the right one.

It should be mentioned that ischemia-reperfusion resulted in blastulation rate decline compared to those of the control and SIM-only groups. The Simvastatin treatment led to an increase in the rate of blastulation compared to that of the IR-only group (Fig 3).

Discussion

It has been shown that the testicular IR-induced oxidative stress can lead to germ cell damage as well as the spermatogenesis disruption (13). It was found that the ROS overproduction during IR was associated with cell membrane injuries and tissue destruction (14). It was also found that ROS could trigger leukocyte activation and the chemotaxis and leukocyte-endothelial adherence following IR (15). The activated leukocytes can also cause increased microvascular permeability, edema and parenchymal cell death through toxic ROS, proteases and elastases production (16).

Evidence from research demonstrates that mammalian spermatozoa are susceptible to ROS-evoked damage due to their plasma membrane unusual lipidic composition, and that the elevated ROS level can lead to sperm abnormality and death (17). It is generally believed that the abnormal spermatozoa are the main sources of excessive ROS generation in semen, and that ROS-producing spermatozoa can cause fertilization and embryo development failures. Accordingly, the observed reductions in the fertilization and blastulation rates in the IR group in the present study may be attributed to the injurious effects of ROS-generating damaged spermatozoa during the in vitro insemination of oocytes (18, 19).

Several experimental studies have already revealed the efficacy of antioxidant therapy in the prevention and/or the attenuation of IR-related injuries in testicular tissue

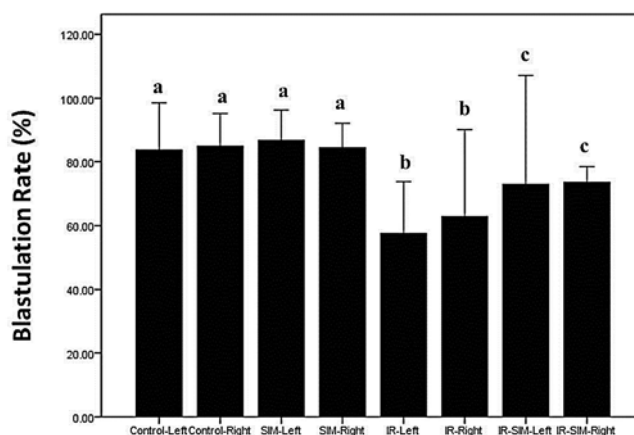


Fig 3. The bilateral effects of the unilateral testicular ischemia-reperfusion on the blastulation rate in all the experimental groups. Different superscripts denote statistical difference at a $p < 0.05$. SIM: Simvastatin; IR: Ischemia-reperfusion

(20-22). Consistent with these findings, the SIM administration in this study caused protection against the IR-induced fertility impairment and the developmental arrest. In line with that, previous reports demonstrated that SIM, as a potent antioxidant, anti-inflammatory and anti-apoptotic agent can ameliorate cadmium (6) and hypercholesterolemia-induced male reproductive disorders (23).

Conclusion

All in all, this study highlighted the repro-protective effects of SIM against the IR-induced fertility impairment as well as the developmental disorders through scavenging ROS and the inhibition of inflammatory and apoptotic events.

Conflict of interest

The authors declare that there are no conflicts to disclose.

References

1. Sharp VJ, Kieran K, Arlen AM. Testicular torsion: diagnosis, evaluation, and management. *Am Fam Physician*. 2013; 88(12): 835-840.
2. Ringdahl E, Teague L. Testicular torsion. *Am Fam Physician*. 2006; 74(10): 1739-1743.
3. Mushtaq I, Fung M, Glasson MJ. Retrospective review of paediatric patients with acute scrotum. *ANZ J Surg*. 2003; 73(1-2): 55-58.
4. Turner TT, Tung KS, Tomomasa H, Wilson LW. Acute testicular ischemia results in germ cell-specific apoptosis in the rat. *Biol Reprod*. 1997; 57(6):1267-1274.
5. Moon C, Kim JS, Jang H, Lee HJ, Kim SH, Kang SS, Bae CS, Kim JC, Kim S, Lee Y, Shin T. Activation of Akt/protein kinase B and extracellular signal-regulated kinase in rats with acute experimental testicular torsion. *J Vet Med Sci*. 2008; 70(4): 337-341.
6. Fouad AA, Albuali WH, Jresat I. Simvastatin treatment ameliorates injury of rat testes induced by cadmium toxicity. *Biol Trace Elem Res*. 2013; 153(1-3): 269-278.
7. Lee J, Lee JR, Youm HW, Suh CS, Kim SH. Effect of preoperative simvastatin treatment on transplantation of cryopreserved-warmed mouse ovarian tissue quality. *Theriogenology*. 2015; 83(2): 285-293.
8. Jalali AS, Najafi G, Mohammadi M, Moeini RM. Simvastatin abates doxorubicin-induced teratozoospermia. *Int J Fertil Steril*. 2014; 8: 57-58.
9. Mohammadi F, Jalali AS, Najafi G, Behfar M. Stereological, morphometric and morphological analyses of bilateral epididymal lipectomy induced changes in mouse testicular histoarchitecture. *J Kermanshah Univ Med Sci*. 2017; 20(4): 141-146.
10. Mogilner JG, Lurie M, Coran AG, Nativ O, Shiloni E, Sukhotnik I. Effect of diclofenac on germ cell apoptosis following testicular ischemia-reperfusion injury in a rat. *Pediatr Surg Int*. 2006; 22(1): 99-105.
11. Jalali AS, Najafi G, Hosseini M, Sedighnia A. Royal jelly alleviates sperm toxicity and improves in vitro fertilization outcome in stanozolol-treated mice. *Iran J Reprod Med*. 2015; 13(1): 15-22.
12. Najafi G, Farokhi F, Jalali AS, Akbarizadeh Z. Protection against cyclosporine-induced reprotoxicity by *Satureja khuzestanica* essential oil in male rats. *Intl J Fertil Steril*. 2016; 9(4): 548-557.
13. Wei SM, Yan ZZ, Zhou J. Protective effect of rutin on testicular ischemia-reperfusion injury. *J Pediatr Surg*. 2011; 46(7):1419-1424.
14. Wei SM, Yan ZZ, Zhou J. Curcumin attenuates ischemia-reperfusion injury in rat testis. *Fertil Steril*. 2009; 91(1): 271-277.
15. Collard CD, Gelman S. Pathophysiology, clinical manifestations, and prevention of ischemia-reperfusion injury. *Anesthesiology*. 2001; 94(6): 1133-1138.
16. Carden DL, Granger DN. Pathophysiology of ischaemia-reperfusion injury. *J Pathol* 2000; 190: 255-266.
17. Aitken RJ, Clarkson JS, Fishel S. Generation of reactive oxygen species, lipid peroxidation, and human sperm function. *Biol Reprod*. 1989; 41(1): 183-197.
18. Said TM, Agarwal A, Sharma RK, Thomas AJ Jr, Sikka SC. Impact of sperm morphology on DNA damage caused by oxidative stress induced by beta-nicotinamide adenine dinucleotide phosphate. *Fertil Steril*. 2005; 83(1): 95-103.
19. Nasr-Esfahani MH, Aitken RJ, Johnson MH. Hydrogen peroxide levels in mouse oocytes and early cleavage stage embryos developed in vitro or in vivo. *Development*. 1990; 109(2): 501-507.

20. Wei SM, Yan ZZ, Zhou J. Beneficial effect of taurine on testicular ischemia-reperfusion injury in rats. *Urology*. 2007; 70(6): 1237-1242.
21. Shahkarimi M, Jalali AS, Behfar M, Najafi G. Doxycycline diminishes unilateral testicular ischemia-reperfusion-induced impairment of epididymal sperm fertilizing capability in mice. *J Reprod Infertil*. 2016; 17: 63-64.
22. Wei SM, Yan ZZ, Zhou J. *Psoralea corylifolia* protects against testicular torsion/detorsion-induced ischemia/reperfusion injury. *J Ethnopharmacol*. 2011; 137(1): 568-574.
23. Shalaby MA, el-Zorba HY, Kamel GM. Effect of alpha-tocopherol and simvastatin on male fertility in hypercholesterolemic rats. *Pharmacol Res*. 2004; 50(2): 137-142.