

**Case Report****Postpartum right ovarian vein thrombosis with extension to the inferior vena cava: A case report**Nidhi Mahajan<sup>1</sup>, Ibrahi Farid<sup>1</sup>, Shanmugavel Chinnakaruppan<sup>2</sup>, Mohamed Khalid Shariff<sup>3</sup>, Soma Mitra<sup>\*,4</sup><sup>1</sup> Obstetric and Gynae Department, Al Khor Hospital, Hamad Medical Corporation, Qatar<sup>2</sup> Radiology Department, Al Khor Hospital, Hamad Medical Corporation, Qatar<sup>3</sup> Internal Medicine Department, AL Khor Hospital, Hamad Medical Corporation, Qatar<sup>4</sup> Obstetrics and Gynae Department, DDU Hospital, New Delhi, India

Received: 4 July 2024 Accepted: 20 Dec 2024

**Abstract**

Postpartum ovarian vein thrombosis (POVT) is a rare yet potentially life-threatening condition that can lead to severe complications and even death. We report the case of a 38-year-old woman, para 5, who presented to the obstetric emergency department on the second day following a vaginal delivery, complaining of right iliac fossa pain, nausea, and loss of appetite. A computed tomography (CT) scan confirmed thrombosis of the right ovarian vein. The patient was managed conservatively with a treatment regimen that included antibiotics and low molecular weight heparin, followed by warfarin therapy. Remarkably, she achieved full recovery without any complications. This case underscores the critical importance of prompt diagnosis and effective management of postpartum ovarian vein thrombosis. Early intervention is essential to significantly reduce the risks of morbidity and mortality associated with this condition. Clinicians should maintain a high index of suspicion for POVT in postpartum patients presenting with abdominal pain and other nonspecific symptoms to ensure timely treatment and favorable outcomes.

**Keywords:** Abdomen, Postpartum Period, Thrombosis, Vena Cava**Introduction**

Postpartum ovarian vein thrombosis (POVT) is a rare but noteworthy complication that may arise following childbirth. (1). The initial diagnosis of postpartum ovarian vein thrombosis is based on a combination of clinical symptoms, particularly abdominal pain and fever, along with imaging studies that confirm the presence of inflammation and thrombosis in the ovarian vein (2). Interestingly, 80-90% of postpartum ovarian vein thrombosis cases involve the right ovarian vein (3). POVT can lead to severe complications, including sepsis and pulmonary embolism, which rank among the leading causes of maternal mortality (3).

Diagnosis of postpartum ovarian vein thrombosis can be challenging because the clinical presentations are often nonspecific and may overlap with other conditions that cause abdominal pain in the postpartum period, such as endometritis, appendicitis, and pyelonephritis. This overlap can complicate the identification of POVT, necessitating a high index of suspicion and thorough evaluation to ensure accurate

diagnosis and timely management (4). The incidence of POVT is estimated to be approximately 1 in 3,000 deliveries, with higher rates reported in cases of vaginal deliveries and multiple pregnancies (5).

The terms "ovarian vein thrombosis" and "ovarian vein thrombophlebitis" are frequently used interchangeably to describe the presence of a clot in the ovarian vein, regardless of whether inflammation is also present (6). Ultrasound is a rapid and cost-effective initial diagnostic tool for POVT, while computed tomography (CT) and magnetic resonance imaging (MRI) are considered the preferred modalities for definitive diagnosis (7).

**Case Presentation**

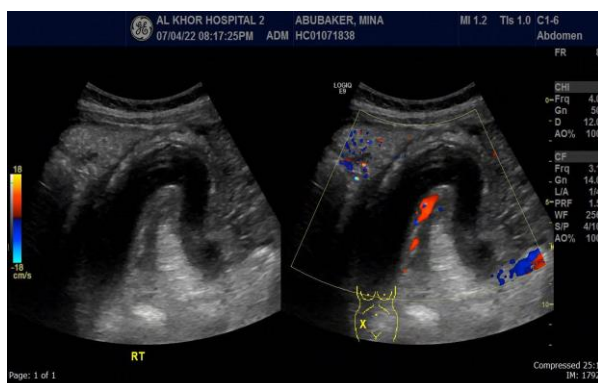
A 38-year-old woman, para 5, presented to the obstetric and gynecological emergency department approximately 9-10 hours after being discharged from the hospital following a vaginal delivery. She reported symptoms of right iliac fossa pain, nausea, and a loss

\*Correspondence author: Dr. Soma Mitra, DGO, DNB DDU Hospital, New Delhi - NA - C3, WZJ / 70 / Beriwalla Bagh, Harinagar, New Delhi

of appetite. The pain had begun during her hospital stay but was initially mild; however, it intensified post-discharge. Notably, she experienced no cough, respiratory distress, fever, chest pain, or gastrointestinal symptoms, and her lochia was normal. Her antenatal history was unremarkable, except for a diagnosis of type II diabetes for the past four years, for which she was taking 1 gram of metformin twice daily. She had been admitted during her second trimester for glycemic control, and insulin was introduced during her pregnancy. Her hemoglobin level was 11.6 g/d, and other blood tests were normal. A high vaginal swab tested positive for *Streptococcus agalactiae*, while an ultrasound indicated normal fetal growth, with an estimated fetal weight of 3.4 kg.

She was admitted at 37 weeks and 5 days' gestation due to mild abdominal pain and underwent induction with prostaglandin, followed by augmentation of labor. Her labor and delivery were uncomplicated, and she received antibiotics during labor as prophylaxis for group B streptococcus (GBS). The following day, she was discharged without any complaints but returned to the emergency department with right iliac fossa pain.

Upon presentation, she was afebrile, with vital signs indicating a pulse of 84 beats per minute, a temperature of 36°C, a respiratory rate of 20 breaths per minute, and a blood pressure of 118/62 mmHg. Physical examination revealed tenderness in the right iliac fossa and rebound tenderness, but no palpable mass was detected. Laboratory tests showed a hemoglobin level of 11.8 g/dL, leukocytosis at  $3.3 \times 10^3/\mu\text{L}$ , and a C-reactive protein level of 83.7 mg/L.

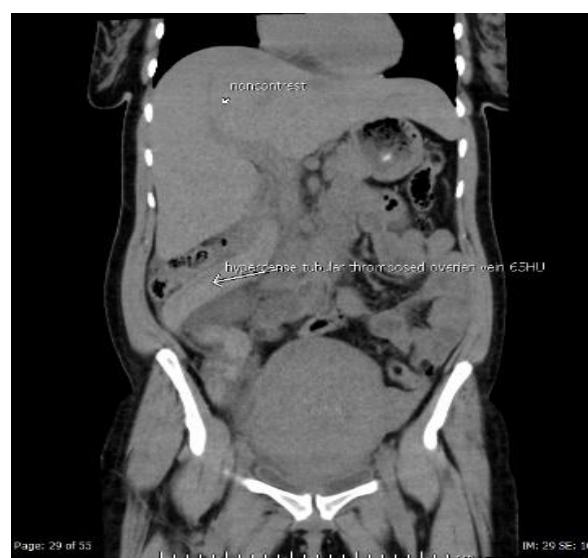

**Figure 1. Ultrasound image showing right dilated ovarian vein**

A vaginal ultrasound demonstrated a dilated right ovarian vein with no detectable blood flow; only part

of the vein was visualized (Figure 1). A CT scan of the abdomen and pelvis revealed a dilated and tortuous right ovarian vein containing a thrombus. A filling defect was noted in the central portion of the inferior vena cava (IVC) at its inferior aspect, and thrombosis was also observed in the right tortuous parametric veins. The length of involvement was 20 cm, with a width of 2.4 cm (Figures A, B, and C). The aorta, hepatic vein, and portal vein appeared normal. The diagnosis was acute right ovarian vein thrombosis with signs of septic thrombophlebitis, indicating a spectrum of septic pelvic thrombophlebitis. Other differential diagnoses, including appendicitis, intestinal obstruction, uropathy, and any pelvic pathology, were ruled out based on the CT findings.

**Figure A. Non-contrast computed tomography (CT) reveals a hyperdense serpiginous tubular**

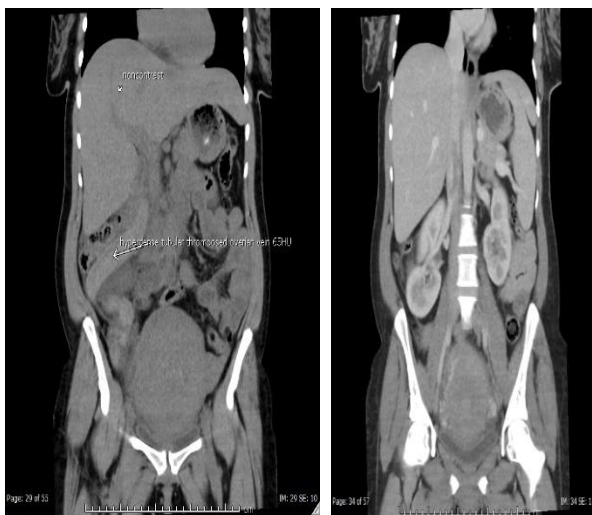

**structure in the retroperitoneum, extending from the anterior aspect of the inferior vena cava (IVC) to the right ovary**

The patient was admitted to the obstetrics and gynecology unit with septic right ovarian vein thrombosis. Upon admission, she received broad-spectrum antibiotics (ceftriaxone 2 g daily and metronidazole 500 mg every 8 hours), low molecular weight heparin (70 mg twice daily), and paracetamol for pain management. Her insulin regimen was adjusted, and warfarin therapy was initiated at 10 mg daily, with bridging anticoagulation using enoxaparin until a therapeutic INR of 2-3 was achieved. A multidisciplinary team, including a vascular surgeon, hematologist, and interventional radiologist, was involved in her care, planning to continue

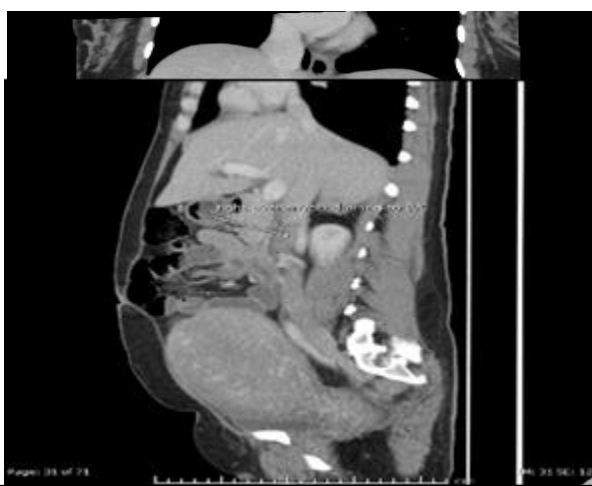
anticoagulation for three months without surgical intervention unless contraindications arose.

Later that evening, the patient developed dyspnea, with oxygen saturation levels falling to 92-93%. The rapid response team was activated, and she presented with tachypnea while maintaining stable blood pressure and a temperature of 36.8°C. To maintain oxygen saturation, nasal oxygen was administered, and normal saline was infused. An urgent CT pulmonary angiogram was conducted to rule out pulmonary embolism, and surgical evaluation was initiated due to rebound tenderness in the right iliac fossa, leading to her transfer to the medical intensive care unit due to a high likelihood of pulmonary embolism.



**Figure B. Post contrast CT venous phase show filling defect in keeping with postpartum right-side ovarian vein thrombosis extending into the inferior vena cava (IVC)**

Laboratory results indicated a white blood cell count of  $14.4 \times 10^3/\mu\text{L}$  and a significant increase in C-reactive protein, rising from 83 mg/L to 400 mg/L. Prothrombin time (PT) and activated partial thromboplastin time (APTT) were prolonged, with PT at 30.5 seconds, APTT at 63.5 seconds, and INR at 1.2.

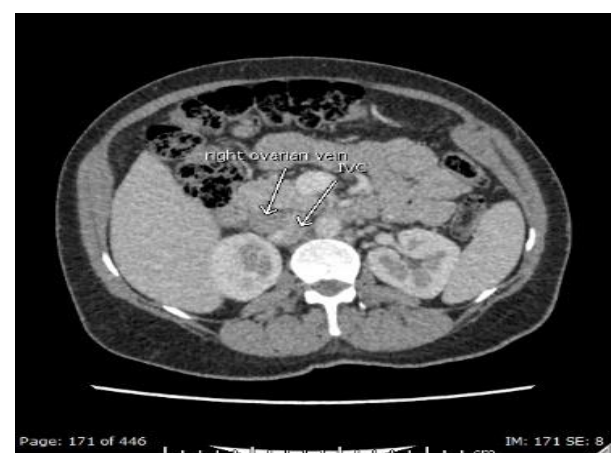

Procalcitonin was measured at 0.24, and renal function tests revealed low magnesium and potassium levels. Factor V screening was negative, and blood cultures showed no growth. An echocardiogram was normal. The patient was stabilized with conservative management, continuing antibiotics while monitoring her INR, magnesium, and potassium levels.

On day three, the patient developed a fever of 38.5°C, prompting a change to piperacillin-tazobactam due to rising inflammatory markers. A repeat pelvic ultrasound indicated an edematous and hypoechoic enlarged right ovary, suggestive of early right ovarian infarction. The obstetrics and gynecology team opted for conservative management without surgical intervention.

**Figure C. Post contrast axial image the drainage of vein to anterior part of the inferior vena cava (IVC).**

After 12 days of hospitalization, the patient was discharged on warfarin at 4 mg daily. Follow-up tests showed hemoglobin at 9.3 g/dL and INR at 2.5, with elevated platelets. JAK2 mutation tests were negative. At her last appointment, five months later, the patient was stable, having completed three months of anticoagulation. She received psychiatric support for low mood and was counseled against using oral contraceptives. The patient is currently well and has become pregnant again, with enoxaparin initiated at the start of her pregnancy.



## Discussion

Pregnancy and the postpartum period significantly increase the risk of thromboembolism, with women facing a 4-6 times higher risk during pregnancy that escalates further postpartum. POVT is closely

associated with Virchow's triad: hypercoagulability, venous stasis, and endothelial injury. Hemostatic changes during pregnancy, such as elevated procoagulant factors (e.g., fibrinogen, factors VII, VIII, X, and von Willebrand factor) and decreased natural anticoagulants (e.g., reduced protein S activity), contribute to this hypercoagulable state (8). These physiological adaptations prepare the body for delivery but also predispose women to thrombotic events.

At term, the ovarian vein's diameter increases threefold compared to non-pregnant women, accompanied by a 60-fold rise in blood volume. These changes can lead to valvular incompetence and venous stasis. Post-delivery, reduced blood flow exacerbates stasis, with the right ovarian vein being particularly vulnerable due to its anatomical characteristics. Risk factors for POVT include multiple gestations, preeclampsia, induced abortion, hormonal therapies (e.g., oral contraceptives or estrogen), malignancies, and pelvic surgeries (9).

POVT typically presents within 10 days postpartum in 90% of cases. Common symptoms include abdominal pain, fever, nausea, and ileus. Pain is often occasionally a palpable mass on examination. Differential diagnoses include appendicitis, peritonitis localized but may radiate, with acute tenderness and, and adnexal torsion, necessitating imaging for accurate diagnosis. Complications of POVT include sepsis, ovarian infarction, renal vein extension, hydronephrosis, pulmonary embolism (with a 33% risk), and a mortality rate of approximately 4.4% (8).

Laboratory findings often reveal leukocytosis and elevated C-reactive protein levels; however, positive blood cultures are rare (10). Ultrasound Doppler serves as a rapid initial diagnostic tool but may have limited sensitivity. Contrast-enhanced CT remains the gold standard for identifying thrombi. MRI is an alternative in cases where CT is contraindicated (11). Management of POVT involves anticoagulation therapy and antibiotics. Broad-spectrum antibiotics are initiated immediately upon diagnosis to address potential infections. Anticoagulation typically begins with intravenous heparin followed by oral warfarin for 3-6 months; low molecular weight heparin is an effective alternative. Inferior vena cava filters may be considered in cases of deep vein thrombosis or pulmonary embolism when anticoagulation is contraindicated (10). In conclusion, prompt recognition

and management of POVT are critical to preventing severe complications such as pulmonary embolism and ovarian infarction. A multidisciplinary approach involving obstetricians, gynecologists, hematologists, radiologists, and other specialists is essential for optimal outcomes.

## Conclusion

Our experience underscores the critical importance of early identification of POVT. Although it is rarely reported, POVT can lead to significant morbidity and mortality if not treated promptly. Women in the postpartum period presenting with unexplained lower abdominal pain, fever, and leukocytosis should be evaluated with ultrasound or CT scans for accurate diagnosis. Maintaining a high clinical suspicion is essential to prevent serious complications such as ovarian infarction and pulmonary embolism, which can be effectively mitigated through timely intervention.

A multidisciplinary approach involving obstetricians, gynecologists, hematologists, radiologists, microbiologists, and, when necessary, interventional radiologists or vascular surgeons is crucial for optimal management. Repeated imaging typically does not influence treatment decisions regarding the type or duration of therapy. Anticoagulation primarily aims to prevent further clot extension rather than thrombolysis. Given the identifiable reversible risk factors during pregnancy, anticoagulation is generally limited to three months; however, cases of unprovoked thrombosis may require longer treatment.

For future pregnancies, antenatal prophylactic anticoagulants are recommended for women with a history of venous thromboembolism related to hormonal contraception or pregnancy, continuing until six weeks postpartum.

## Acknowledgements

We extend our heartfelt gratitude to the Obstetrics and Gynecology Department, Radiology Department, and Internal Medicine Department at Al Khor Hospital, Hamad Medical Corporation, Qatar, for their unwavering support and collaboration throughout this study. We also sincerely thank the Obstetrics and Gynecology Department of DDU Hospital, New Delhi, for their valuable contributions. Their expertise and assistance were instrumental in the successful



completion of this work, and we deeply appreciate their dedication to advancing medical research and patient care.

## Conflicts of Interest

We have no commercial or financial gains for this study.

## References

1. Dunphy L, Tang AW. Ovarian vein thrombosis in the postnatal period. *BMJ Case Reports CP* 2021; 14(6): e243872.
2. Jha A, Khatiwada A, Sharada K. Ovarian vein thrombosis in a postpartum female: A case report. *Radiology Case Reports* 2024; 19(11): 4759-61.
3. Cheung W, Stegwee S, van Hamont D, Visser J. Postpartum ovarian vein thrombosis with left renal venous infarction after vaginal delivery. *BMJ Case Reports CP* 2024; 17(3): e258877.
4. Mahfoud H, Etber A, Errmili K, Khairoun S, Zeraidi N, Baidada A. Ovarian vein and inferior vena cava thrombosis after vaginal delivery: A case report. *Case Reports in Women's Health* 2024; 41: e00592.
5. Burns RN, Vadlamudi G, Ginsburg J, Velez L. The Fourth Trimester: Emergencies in the Postpartum Period. *Emergency Medicine Reports*. 2024.
6. Stancheva B, Boneva B, Stankev M, Lukanova D. Navigating Postpartum Venous Thromboembolism: A Case of Thrombophilia, Bleeding Complications, and Chronic Inferior Vena Cava Syndrome. *Cureus* 2024; 16(10).
7. Akçay A, Dönmez Z, Peker AA, Toprak H, Gültekin MA. Diagnostic utility of Magnetic Resonance Imaging in discriminating immature teratoma: Insights from a case series. *Journal of Clinical Ultrasound*. 2024.
8. Riva N, Calleja-Agius J. Ovarian vein thrombosis: a narrative review. *Hämostaseologie*. 2021; 41(04):257-66.
9. Dougan C, Phillips R, Harley I, Benson G, Anbazhagan A. Postpartum ovarian vein thrombosis. *Obstetrician & Gynaecologist* 2016; 18(4).
10. Gao Q, Xiong J, Jiang H. Pharmacologic treatment of a postpartum ovarian vein thrombosis: Case report. *Medicine* 2023; 102(32): e34711.
11. Ahmed M, Mendha T, Do V, Carlan S, Madruga M. Ovarian vein thrombosis: an unusual cause of abdominal pain in breast cancer. *Cureus* 2023; 15(4).