

Endometrial hyperplasia in Indian perimenopausal women: A retrospective analysis

Beenish Qureshi¹, Saika Amreen^{2,*}, Rabia Khurshid¹, Rifat Amin¹

¹ Department of Obstetrics & Gynecology, Sher-i-Kashmir Institute of Medical Sciences (SKIMS), India

² Department of Radiology & Imaging Technology, Sher-i-Kashmir Institute of Medical Sciences (SKIMS), India

Received: 29 Jan 2021 Accepted: 17 Sep 2021

Abstract

Background: Perimenopause is the time between changes in menstrual cycle toward menopause or permanent infertility. The aim of this study was to analyze the clinical, sonographic, and histological characteristics of perimenopausal women with abnormal uterine bleeding that was subsequently managed surgically.

Methods: This retrospective study used existing data from 102 perimenopausal female with abnormal uterine bleeding, who underwent surgical procedure during one-year period of a tertiary care hospital in Kashmir, India from Jan 2018 to April 2019. Standard sagittal views of the uterus were used to measure the endometrial thickness using transvaginal sonography (TVS). Dilatation and Curettage (D&C) was performed for obtaining endometrial tissue for pathological evaluation.

Results: The most common complaint was menorrhagia with a mean duration of 12 months. The maximum endometrial thickness was seen with patients who finally had a diagnosis of endometrial hyperplasia with atypia and polyps. Patients with normal endometrium on pathology and those with chronic endometritis had similar endometrial thickness on TVS. Endometrial thickness was correlated with the severity of the lesion with an average thickness of 3 mm in atrophy, 10-12 mm in hyperplasia, and 18 mm in carcinoma.

Conclusion: Endometrial hyperplasia needs active and vigilant surveillance for its diagnosis and management. In perimenopausal women, the endometrial thickness is fickle and may not reflect the development of atypia.

Keywords: Atypical endometrial hyperplasia, Endometrial neoplasms, Endometrial Hyperplasia, Hyperplasia, Perimenopause

Introduction

An abnormal overgrowth of the endometrium is described as endometrial hyperplasia, which may be focal or diffuse (1). It is a spectrum of changes affecting both the glandular and stromal elements of the endometrium with histological diversity (2). Atypical endometrial hyperplasia is an established precursor to endometrial cancer with 23–30% of patients progressing to cancer (3). The possibility of a coexisting endometrial carcinoma in patients with endometrial hyperplasia with atypia cannot be completely excluded by curettage, with low

interobserver agreement among pathologists. In order to evaluate the possibility of concurrent endometrial cancer, transvaginal ultrasound (TVS) can often guide the diagnostic approach in these patients (3, 4). However, the most widely utilized method of surgical management is hysterectomy (1, 5). Although TVS has been lavishly utilized for the evaluation of post-menopausal endometrium, the same cut off values have not been assessed for the perimenopausal endometrium (6). The aim of this study was to analyze the clinical, sonographic, and histological characteristics of perimenopausal women with abnormal uterine bleeding, which was subsequently managed surgically.

*Correspondence author: Dr. Saika Amreen, Department of Obstetrics & Gynecology, Sher-i-Kashmir Institute of Medical Sciences (SKIMS),

Materials & Methods

This retrospective study used existing data from routine investigations and interventions of a tertiary care hospital in Kashmir, India from Jan 2018 to April 2019. The ethics committee of Sher-i-Kashmir Institute of Medical Sciences (SKIMS) in India approved this study. Patients with the chief complaint of abnormal uterine bleeding, who underwent surgical procedure for over a period of one year, were included in the study. TVS was performed by radiologists with a 7-10 MHz endovaginally probe using Aloka Prosound SSD 3500 SX. Standard sagittal views of the uterus were used to measure the endometrial thickness by electronic calipers from “echo to echo”. In case any fluid was present in the endometrial canal, both layers of the endometrium were measured separately, and the values were added for the final endometrial thickness. Post-menopausal females without a complete TVS record or histological diagnosis were excluded from the study. Only patients for whom TVS was performed before day 10 of the cycle were included. Dilatation and curettage (D&C) was performed for obtaining endometrial tissue for pathological evaluation. MedCalc Statistical Software version 18.9.1 was used for analysis.

Results

We included 102 patients who had undergone surgical procedure over the period between 2018 and 2019 in Kashmir, India. The mean age was 54 years. The most common complaint (32%) was menorrhagia with a mean duration of 12 months of symptoms. The lowest endometrial thickness was 5 mm, while the highest was 38 mm with a SD of 8.9 (Fig 1). The maximum endometrial thickness was seen in patients who finally had a diagnosis of endometrial hyperplasia with atypia and polyps (Fig 2). Patients with normal endometrium on pathology and those with chronic endometritis had similar endometrial thickness on TVS with no significant statistical difference (Fig 3). On comparing the mean endometrial thickness in patients with and without a final diagnosis of hyperplasia, the result was not statistically significant. Thus, we were unable to establish a new or confirm an existing endometrial thickness threshold to suggest hyperplasia in this group of perimenopausal patients.

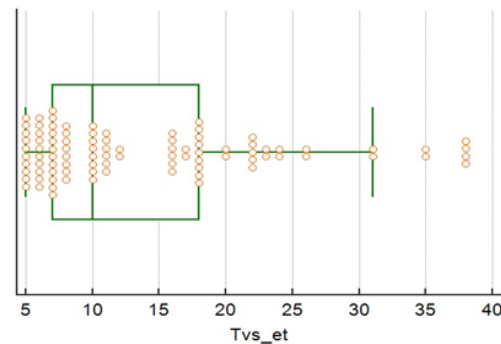


Figure 1. Box and whisker plot of endometrial thickness

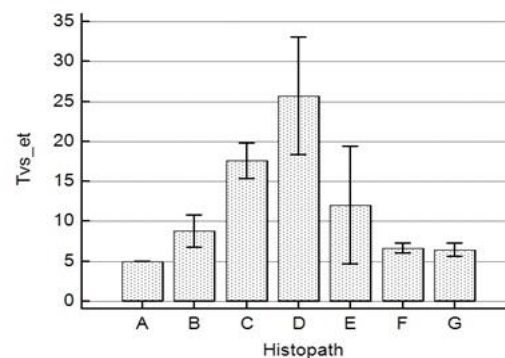


Figure 2. Comparison of endometrial thickness to the final histopathology

A: Adenomyosis, B: Fibroids, C: Endometrial hyperplasia, D: Endometrial hyperplasia with atypia, E: Endometrial polyps, F: Chronic endometritis, G: Normal

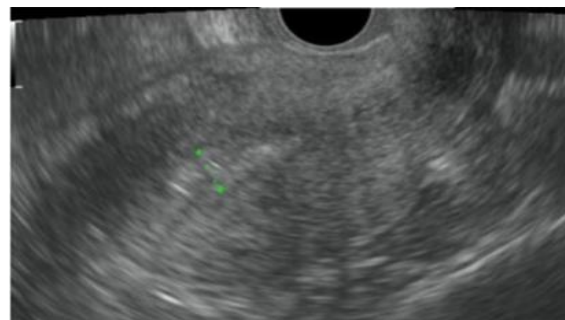


Figure 3: Transvaginal ultrasound sagittal view showing thickened endometrium in a patient with final histopathology of hyperplasia without atypia

Patients on tamoxifen treatment (n=10) had a mean endometrial thickness of 15mm. All these patients had been under treatment for over twelve months. Two of these patients had hyperplasia with atypia, while the rest had hyperplasia without atypia (n=8). Patients on

hormone replacement therapy (HRT) (n=20) had a mean endometrial thickness of 13mm. Two of these patients had atypia, two had chronic endometritis, while the rest had hyperplasia (n=16). Nulliparous patients (n=6) had a mean endometrial thickness of 23 mm with four patients having hyperplasia and two patients having atypia.

Discussion

Endometrial thickness appears to correlate with the severity of the lesion with an average thickness of 3 mm in atrophy, 10-12 mm in hyperplasia and 18 mm in carcinoma. By using a cut-off of 5 mm, it is thought that the majority of cases of both endometrial carcinoma and endometrial hyperplasia should be identified and investigated further (1, 5). When an endometrial biopsy retrieves insufficient tissue for diagnosis and the endometrial thickness is 4 mm, no additional diagnostic tests are required. Conversely, it is recommended to obtain a histologic specimen using D&C when the endometrial thickness is 4 mm (4). Risk assessment using a combination of individual patient characteristics and endometrial thickness has been evaluated and suggested to be most cost-effective for selection of a second-line strategy. Efficient risk assessment strategies may reserve a costly fast-track diagnostic work-up for women with ultrasound findings highly suspicious of endometrial thickness, while women with an ultrasonic low risk of malignancy may be evaluated in a standard diagnostic work-up (7).

The mean age of the subjects in our study was 54 years. Studies have suggested that age is a significant factor in the prediction of cancer (3). It has been suggested that the post-menopausal group has a higher risk of endometrial cancer than hyperplasia, which makes prediction more difficult (4). Most women diagnosed with endometrial hyperplasia suffered from abnormal uterine bleeding including menorrhagia, inter menstrual bleeding or postmenopausal bleeding (1, 5). The incidence of endometrial hyperplasia was 33% in our study, and for atypia, it was 12%, which is in line with the previous data in literature. Since our study only included patients who underwent a surgical procedure, the actual incidence may be quite higher (4).

Studies by Ferenczy and Gelfand (8) have defined two tracks for the endometrial development, namely,

hyperplasia or neoplasia. This approach denies the existence of a continuum of changes and emphasizes that the only morphological factor distinguishing benign endometrial lesions from those with malignant potential was cytological atypia. This conclusion was supported by a number of quantitative studies of cytodynamics, nuclear morphometric and DNA content, hence making the histological diagnosis essential for the exclusion of carcinoma in cases of hyperplasia with or without atypia (2). As per latest guidelines, WHO differentiates between two categories of endometrial hyperplasia as a reflection of molecular genetic changes: 1) hyperplasia without atypia and 2) atypical hyperplasia/endometrioid intraepithelial neoplasia (6).

Hyperplasia without atypia is benign and exhibits no relevant genetic changes. However, progression to invasive disease may occur in less than three. Atypical endometrial hyperplasia, on the other hand, exhibits many of the mutations typical for invasive endometrial cancer (6). Hence, hyperplasia without atypia should generally be treated conservatively. The risk factors for endometrial hyperplasia are the same as those for endometrial carcinoma. Unopposed estrogen, which can be endo or exogenous, has a mutagenic and carcinogenic effect on stromal and glandular cells of the endometrium, leading to hyperplastic lesions. Other risk factors for endometrial carcinoma include increased body mass index (BMI), nulliparity, chronic anovulation, early menarche, late onset of menopause, and diabetes (4, 5). We did not find BMI to be statistically significant or correlate to final diagnose as in other studies (3). Only a small percentage of our patients had hypertension and/or diabetes that were statistically significant in order for us to make a conclusion.

It has been shown that 5.3% of women taking cyclical estrogen and progestogen developed endometrial hyperplasia with 0.7% developing atypical hyperplasia (1, 5). All of the patients who were nulliparous had the final diagnosis of endometrial hyperplasia with two showing atypia as well. Since this was a retrospective study, we did not have access to the particular fertility treatments these patients may have undergone several years ago. This denotes an area that needs further probing and investigations.

Tamoxifen is a selective estrogen receptor modulator (SERM), widely used as adjunctive

treatment in postmenopausal women with estrogen receptor positive breast cancer. The primary therapeutic effect of tamoxifen is its anti-oestrogenic effects on the breast; however, it has pro-oestrogenic effects on the uterus and bone. The risk of developing endometrial cancer in postmenopausal women taking tamoxifen is thought to be two to three times higher than the general population risk (1, 5). We found two patients on tamoxifen with atypia. As such, routine TVS screening should be performed on asymptomatic, postmenopausal breast cancer tamoxifen-treated patients. Other reports have claimed that TVS is of limited value in the evaluation of endometrium of such patients due to a false-positive sonographic appearance of a thick endometrium and a discrepancy between the sonographic and histologic findings that were described in these patients perhaps due to stromal edema (9).

Several studies have implicated the use of a cut off value for endometrial thickness on TVS. Gull et al. found that no endometrial cancers would have been missed (using a cutoff level of ≤ 4 mm) if TVS measurement of the endometrial thickness had been performed. The fact that women were followed up for ten years after the primary referral could confirm the clinical efficacy of TVS measurement of endometrial thickness as a means of excluding endometrial disease in women with post-menopausal bleeding (10). Recommendations, however, vary widely. Some authors propose hysterectomy for patients with prior hyperplasia before starting tamoxifen, while others are comfortable with ultrasound and pipette biopsy for monitoring (11).

Research findings illustrated that 60% of women with a preoperative diagnosis of atypical endometrial hyperplasia had undiagnosed endometrial cancer when the uterus was examined by a pathologist after hysterectomy (3). In our study, patients with the diagnosis of endometrial hyperplasia had a mean endometrial thickness of 16 mm, while those with atypia had a mean endometrial thickness of 24 mm. It is imperative to note that all these patients were perimenopausal. One of the biggest limitations of TVS is that although the endometrium changes with the phase of the menstrual cycle in a menstruating woman, the fluctuating levels of estrogen in perimenopausal may actually cause the endometrium to be often thicker than it will be several years after menopause (11). A

cut off value may help improve the prediction of endometrial hyperplasia, but it may cause unnecessary interventions in normal women. This is the basic reason for the evaluation of ancillary features that may help improve prediction. The International Endometrial Tumor Analysis (IETA) group, formed in Chicago in 2008, designed a standardized consensus with the aim of approving terms and definitions that describe ultrasound findings in the uterine cavity, and put forward recommendations that help the prediction and diagnosis of endometrial pathology. In addition, endometrial thickness, vascularization, and patient clinical variables were used to differentiate between benign and malignant endometrium in women with postmenopausal bleeding (12).

We included any documentation of an ill-defined endometrium-myometrium interface and heterogeneous endometrial echogenicity. These characteristics have been described as the best ultrasound variables for predicting endometrial malignancy in a study. Disrupted junction zone was of bad prognosis as well (12). However, few scholars described these patterns unreliable and variable (7). We did not find any statistically significant data pertaining to these findings in our study. Perhaps, it points to the fact that we did not include patients with a preoperative diagnosis of endometrial carcinoma in our study and incidentally none of the included patients had frank carcinoma. Also, we found little information whether these patients had adenomyosis or not. It is pertinent to mention that the nagging question is what is the probability of malignancy. Though the presence of endometrial hyperplasia is a risk factor for progression to endometrial carcinoma, some argue that endometrial hyperplasia is a precursor lesion in the natural history of endometrial carcinoma and that endometrial carcinoma may already be present in a significant number of women with a tissue diagnosis of endometrial hyperplasia. Studies have found rates of concurrent carcinoma in women undergoing hysterectomy for endometrial hyperplasia to range from 17% - 52% (5). Thus, the management of atypia is becoming aggressive in view of its risk to progress to endometrial carcinoma. It is prudent that the endometrial margins are evaluated for disruption or increased vascularity, and even negative findings are documented. However, the evaluation of the endo-

myometrial junction may be difficult in women with adenomyosis or in images of low quality (7).

There is currently no routine screening test for endometrial cancer or its precursor lesions. It is widely accepted that endometrial sampling may not give a representative picture of the entire endometrial cavity and endometrial cancer can be missed even when a TVS was suggestive (4, 5, 11). A vintage study recommended a repeat TVS after a year if endometrial thickness is only 1 mm, curettage for endometrial thickness >4mm and for the rest 2-3 mm, a TVS once every three months for patients with post-menopausal bleeding (13). However, this dictum does not apply to the hormonally mercurial peri menopausal patients. Endometrium can be much thicker than anticipated and still be without atypia. The existing literature suggests that patients who have been diagnosed with atypical endometrial hyperplasia may have concurrent undiagnosed cancer- with the rate varying from 10-52% (3, 4). This wide range demands a crucial decision-making moment where the possibility of cancer in patient is a toss of a coin. TVS may help us find the probability of cancer and hence help in decision making. Patients with a low risk for malignancy can be assured and kept on standard care without a need for close follow-up. This can help both the economical and emotional costs of over calling (7). Such a decision is more important in countries like ours with meager health resources. The importance of early detection, however, cannot be overemphasized as these patients have a sharp decline in survival rate once the stage goes up (13). The key is to identify the earliest change of atypia to carcinoma using the tools we have and improving them. Another important issue remains the preservation of fertility in patients when diagnostic feature may not favor conservative management (6).

Our study has some limitations. Being retrospective, we did not have information about prior body habitus/ obesity, family history, early history of polycystic disease or syndromic presentations, unless specifically mentioned. These have been associated, albeit variably in the previous literature (4, 9). Further studies with a prospective design can help assess these associations.

Conclusion

Endometrial hyperplasia is an elevated glandular to stromal component of the endometrium with varied

degrees of proliferation. It needs active and vigilant surveillance for its diagnosis and management. Though TVS is a barndoor procedure, its utilization needs to be amplified and more characteristics should be sought for helping the prediction of atypia. The endometrial thickness is fickle and may not reflect the true development of atypia in perimenopausal women. Perhaps the development of a scoring system, which considers a combination of findings on transvaginal ultrasound and not just the endometrial thickness or a cut-off value, is the need of the hour for these patients.

Acknowledgements

We would like to appreciate the health center of Sher-i-Kashmir Institute of Medical Sciences (SKIMS) in India for the confirmation of this project. We are also thankful to our colleagues at the tertiary care hospital in Kashmir for their cooperation in the treatment and care of these patients.

Conflicts of Interest

The authors state that there is no conflict of interest.

References

1. Moore E, Shafi M. Endometrial hyperplasia. *Obstet Gynaecol Reprod Med.* 2013;23(3):88-93.
2. Marsden DE, Hacker NF. Optimal management of endometrial hyperplasia. *Best practice & research Clinical obstetrics & gynaecology.* 2001;15(3):393-405.
3. Antonsen SL, Ulrich L, Høgdall C. Patients with atypical hyperplasia of the endometrium should be treated in oncological centers. *Gynecologic oncology.* 2012;125(1):124-128.
4. Armstrong AJ, Hurd WW, Elguero S, Barker NM, Zanotti KM. Diagnosis and management of endometrial hyperplasia. *Journal of minimally invasive gynecology.* 2012;19(5):562-571.
5. Herman MC, Mol BW, Bongers MY. Diagnosis of heavy menstrual bleeding. *Women's health (London, England).* 2016;12(1):15-20.
6. Emons G, Beckmann MW, Schmidt D, Mallmann P. New WHO Classification of Endometrial Hyperplasias. *Geburtshilfe und Frauenheilkunde.* 2015;75(2):135-136.

7. Dueholm M, Hjorth IMD, Dahl K, Pedersen LK, Ørtoft G. Identification of endometrial cancers and atypical hyperplasia: Development and validation of a simplified system for ultrasound scoring of endometrial pattern. *Maturitas*. 2019 May;123:15-24.
8. Ferenczy A, Gelfand MM. Outpatient endometrial sampling with Endocyte: comparative study of its effectiveness with endometrial biopsy. *Obstetrics and gynecology*. 1984;63(3):295-302.
9. Markovitch O, Tepper R, Fishman A, Shapira J, Aviram R, Cohen I. The value of transvaginal ultrasonography in the prediction of endometrial pathologies in asymptomatic postmenopausal breast cancer tamoxifen-treated patients. *Gynecologic oncology*. 2004;95(3):456-462.
10. Gull B, Karlsson B, Milsom I, Granberg S. Can ultrasound replace dilation and curettage? A longitudinal evaluation of postmenopausal bleeding and transvaginal sonographic measurement of the endometrium as predictors of endometrial cancer. *American journal of obstetrics and gynecology*. 2003;188(2):401-8.
11. Hannemann MM, Alexander HM, Cope NJ, Acheson N, Phillips A. Endometrial hyperplasia: a clinician's review. *Obstet Gynaecol Reprod Med*. 2010;20(4):116-120.
12. Madkour NM. An ultrasound risk-scoring model for prediction of endometrial cancer in postmenopausal women (using IETA terminology). *Middle East Fertil Soc J*. 2017;22(3):201-205.
13. Osmers R, Völksen M, Schauer A. Vaginosonography for early detection of endometrial carcinoma? *Lancet (London, England)*. 1990 Jun 30;335(8705):1569-1571.