

Pancreatic pseudocyst complicating pregnancy: A rare clinical presentation

Ariba Moin¹, Alina Moin¹, Hira Maab¹, Laila Tul Qadar¹, Sarush A. Siddiqui¹, Saad Khalid^{1*}¹Department of Internal Medicine, Dow University of Health Sciences, Civil Hospital Karachi, Karachi, Pakistan

Received: 11 May 2021 Accepted: 27 Jun 2021

Abstract

The case report: Pancreatic pseudocyst is an encapsulated collection of enzymatic fluid with a well-constructed inflammatory wall bounded by fibrous tissues. However, this remains a rare occurrence in the setting of pregnancy, occurring in as low as 1 in 60,000 gravidas. With such a dearth in the obstetric presentation of pancreatic pseudocysts, no standard treatment guidelines to cater to the condition have been established. In this report, a 24-year-old patient was presented with upper abdominal pain, fever, and nausea in the 24th week of gestational age, which was later affirmed as a pancreatic pseudocyst on magnetic resonance imaging (MRI). The MRI abdomen demonstrated a well-defined cystic mass measuring 9.5 x 6.0 cm with smooth margins, suggestive of a pancreatic pseudocyst. The patient underwent successful ultrasound (U/S)-guided pseudocyst drainage at 33rd weeks of gestation. Following close antenatal monitoring, she safely delivered a viable male infant at 36th weeks via an emergency cesarean section (C-section).

Keywords: Pancreatic pseudocysts, Pregnancy, Preterm labor

Introduction

Acute and chronic pancreatitis as well as abdominal trauma all play a crucial role in the development of pancreatic pseudocysts. Pseudocysts develop in just 7% of cases of acute pancreatitis as the confined fluid disintegrates spontaneously (1). Initially, the fluid is poorly encapsulated. Hence, a 4 to 6-week observation period helps in deciding whether the fluid collection has healed on its own or if the cyst wall has matured to allow surgical drainage. The risk of complications increases with symptomatic and large (>6cm) pancreatic pseudocysts; therefore, these cases will be in urgent need of internal drainage (2). Spontaneous healing of pseudocysts is uncommon in chronic pancreatitis, and these must be drained as urgently as possible as the risk of fatal complications proportionally evolves with time (3). Options for drainage include surgical, endoscopic, and percutaneous. Current statistics depict that the

percutaneous drainage of pseudocysts is the least successful compared to its alternatives and has considerable disadvantages in terms of higher morbidity and mortality (4). Minimally invasive management options for pancreatic pseudocysts include endoscopic drainage. Currently, it remains the preferred treatment resort (5). Surgical decompression is used if endoscopic treatment fails.

Pancreatic pseudocyst during pregnancy is a daunting situation. It is a challenge as diagnostic and therapeutic options are restricted in pregnancy; each of which comes with its pros and cons. Radiologic investigations must be well thought to minimize the potential risk to the fetus. Also, operative interventions need to be planned with great caution. We present a report of the use of endoscopic retrograde cholangiopancreatography (ERCP), followed by successful ultrasound (U/S)-guided drainage of pancreatic pseudocyst in a pregnant female.

*Correspondence author: Dr. Saad Khalid, Department of Internal Medicine, Dow University of Health Sciences, Baba-e-Urdu Road, Saddar,

Case Report

A 24-year-old primigravida, with a one-day history of upper abdominal pain, fever, and nausea at the 24th week of gestation, referred to the health center. Her past medical history was unremarkable, except that she was given progesterone treatment for a likely abortion at the 12th week of gestation. On admission, her temperature was 100°F, the pulse rate was 96 beats/min, and the blood pressure was 106/72 mmHg. On examination, there was tenderness in the right hypochondrium and epigastric region with normal bowel sounds. Her obstetric examination was corresponding to date. Her total leukocyte count (TLC) was raised (17600/mm³); liver function tests (LFTs) and triglycerides (TGs) were normal. Serum amylase was 140 IU/dl, and serum lipase was 210 IU/dl. The U/S of whole abdomen showed a cystic mass in the right hypochondrium. A gastroenterologist was taken on board. Magnetic Resonance Imaging (MRI) was suggested, which showed a well-capsulated cyst in the tail of the pancreas medial to the spleen and close to the greater curvature of the stomach. A well-defined cystic mass measuring 9.5 cm x 6.0 cm, with smooth margins was found, which was suggestive of a pancreatic pseudocyst (Figure 1).

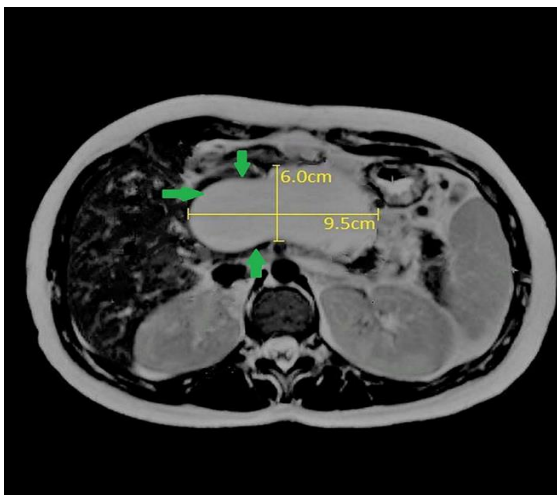


Figure 1. Axial T2-weighted MRI of a pancreatic pseudocyst. The green arrows point to a 9.5 x 6 cm fluid-containing, encapsulated lesion adjacent to the body of the pancreas.

Due to the risk of preterm labor, the patient was initially managed conservatively with intravenous (I/V) antibiotics and hydration. As the patient became asymptomatic and biochemically stable, she was

counseled regarding her findings, put on a controlled diet, and was advised to have a regular antenatal follow-up with sequential antepartum ultrasound of the pseudocyst. She was readmitted at the 28th week of gestation with complaints of vomiting, nausea, and vaginal bleeding. Her investigations showed elevated random blood glucose levels of 236 mg/dL, LFTs were normal, serum amylase was 280 IU/dl and serum lipase was 290 IU/dl. The patient was given supportive treatment and discharged on a controlled diet. The pregnancy continued smoothly; however, at the 33rd week, she was readmitted with complaints of vomiting and severe abdominal pain. Her LFTs were normal, and serum amylase was 290 IU/dl, with blood glucose levels of 391 mg/dL. The patient underwent blood sugar charting and was placed on insulin treatment. ERCP was decided and carried out; the stomach and duodenum appeared normal with some discharge seen coming from the ampullary orifice. The pancreatic duct was selectively cannulated and appeared normal. A small sphincterotomy was performed and a single pig-tail pancreatic stent was placed. In the following day, the patient underwent U/S-guided pancreatic pseudocyst drainage. A catheter was placed and 15 cc of pus was drained from the pseudocyst. Post-draining U/S showed the complete collapse of the cyst.

Three weeks later, the follow-up U/S imaging of the abdomen showed no free fluid in the peritoneal cavity. At the 35th week of gestation, the doppler U/S for fetal wellbeing showed a small for dates fetus with no placental insufficiency. The patient was admitted again five days later, at the 36th week of gestation, with complaints of severe vomiting and abdominal pain. Immediate supportive treatment was given and the cardiotocograph revealed fetal distress. As the patient was not in labor, an emergency C-section through Pfannenstiel incision was done and a small for dates but a healthy male baby, weighing 2.0 kg was delivered safely. The patient was discharged on the 7th postoperative day after the removal of the stitches.

Discussion

In general, pancreatic pseudocysts develop, as a complication, 3 to 4 weeks after the onset of acute pancreatitis, and are usually manifested by an epigastric mass and sensation of fullness (6). The complications of pseudocysts include bleeding, fistula formation, abscess, rupture, and extension (7, 8). In our

case, the pancreatic pseudocyst was diagnosed at the 24th week of pregnancy, following a short history of upper abdominal pain, fever, and vomiting.

There is limited information regarding the management of pancreatic pseudocysts in pregnancy. The natural history and treatment of pancreatic pseudocysts appear to be the same as in non-pregnant patients and are based on clinical findings, the stage, the size of the pseudocyst, and the absence or presence of symptoms or complications (9). Treatment, in general, includes observation, invasive techniques such as percutaneous drainage, endoscopic drainage, and invasive surgical intervention (10). In our patient, due to the risk of preterm labor, surgical intervention was denied until the 33rd week of pregnancy, at which an ERCP was performed due to an increase in cyst size. Categorically, pseudocysts with a diameter less than 4cm remain either clinically stable or resolve spontaneously in 30% to 40% of cases; however, serious complications may arise in 10% of such cases (9). Therefore, watchful management of pseudocysts of diameters between 4-6cm is required to ensure that they remain asymptomatic or stable on follow-up imagery (11).

Pseudocysts greater than 6 cm and lasting for more than 6 weeks are usually managed by an endoscopic percutaneous, or surgical approach (12). Endoscopic ultrasound-guided drainage is performed by establishing a communication between the pseudocyst and stomach or small intestine. One such method is ERCP, which can be used to open the sphincters of the pancreatic valve ducts, thereby decompressing the collected fluid and aiding in stent placement (13). We also performed an ERCP and U/S-guided drainage in our patient with good results. However, the patient developed glucose intolerance and hyperglycemia, which required prompt insulin therapy.

Surgery remains the standard method of drainage of pancreatic pseudocysts; however, surgical intervention was contraindicated due to our patient's ongoing pregnancy. Cesarean section may be the best mode of delivery to prevent rupture of undrained pseudocysts (9). While many pregnant patients are managed conservatively until delivery, our patient became symptomatic, and therefore had to undergo antepartum endoscopic U/S-guided drainage, and later a C-section was performed due to fetal distress.

Conclusion

The majority of patients with pancreatic pseudocysts have a history of pancreatitis or risk factors; our patient, nonetheless, had no such complaints. While most cases are managed conservatively, percutaneous and endoscopic drainage are favorable antepartum treatment options, depending on the patient's condition. Despite the interventions available, the risks of preterm labor due to rupture of pancreatic pseudocysts remains an ongoing concern for both obstetricians and gastroenterologists.

Acknowledgements

None.

Conflicts of Interest

The authors certify that there is no conflict of interest with any financial organization regarding the materials discussed in the manuscript.

References

1. Farias GFA, Bernardo WM, De Moura DTH, Guedes HG, Brunaldi VO, Visconti TAC, et al. Endoscopic versus surgical treatment for pancreatic pseudocysts: Systematic review and meta-analysis. *Medicine*. 2019 Feb;98(8): e14255.
2. Udeshika WAE, Herath H, Dassanayake SUB, Pahalagamage SP, Kulatunga A. A case report of giant pancreatic pseudocyst following acute pancreatitis: experience with endoscopic internal drainage. *BMC research notes*. 2018 Apr 27;11(1):262.
3. Seicean A, Vultur S. Endoscopic therapy in chronic pancreatitis: current perspectives. *Clinical and experimental gastroenterology*. 2015;8:1-11.
4. Szakó L, Mátrai P, Hegyi P, Pécsi D, Gyöngyi Z, Csupor D, et al. Endoscopic and surgical drainage for pancreatic fluid collections are better than percutaneous drainage: Meta-analysis. *Pancreatology : official journal of the International Association of Pancreatology (IAP)* [et al]. 2020 Jan;20(1):132-141.
5. Sileikis A, Beiša A, Zdanytė E, Jurevičius S, Strupas K. Minimally invasive management of pancreatic pseudocysts. *Wideochirurgia i inne techniki maloinwazyjne = Videosurgery and other miniinvasive techniques*. 2013 Sep;8(3):211-215.

6. Li CC, Hsu CW, Li CZ, Kuo SM, Wu YC. Successful treatment of a pancreatic pseudocyst accompanied by massive hemothorax: a case report. *Journal of medical case reports*. 2015 Dec 29;9:295.
7. Kim KO, Kim TN. Acute pancreatic pseudocyst: incidence, risk factors, and clinical outcomes. *Pancreas*. 2012 May;41(4):577-581.
8. Shaker AS, Qazi S, Khankan A, Al-Muaikeel M. Percutaneous approach for removal of a migrated cystogastric stent from a pancreatic pseudocyst: A case report and review of the literature. *Journal of radiology case reports*. 2016 Feb;10(2):18-25.
9. Bansal VK, Misra MC, Goswami A, Garg P, Yonjen T, Kilambi R. Laparoscopic management of pseudocyst of the pancreas in a pregnant patient. *Surgical laparoscopy, endoscopy & percutaneous techniques*. 2012 Feb;22(1):e37-38.
10. Babu GR, Venkatesh S, Ramakrishnan K, Jain P. Clinical study and management of pseudocyst of pancreas. *Int Surg J*. 2017;4(4):1426-1430.
11. Sheng QS, Chen DZ, Lang R, Jin ZK, Han DD, Li LX, et al. Laparoscopic cystogastrostomy for the treatment of pancreatic pseudocysts: a case report. *World journal of gastroenterology*. 2008 Aug 14;14(30):4841-4843.
12. Nealon WH, Walser E. Main pancreatic ductal anatomy can direct choice of modality for treating pancreatic pseudocysts (surgery versus percutaneous drainage). *Annals of surgery*. 2002 Jun;235(6):751-758.
13. Varadarajulu S, Christein JD, Wilcox CM. Frequency of complications during EUS-guided drainage of pancreatic fluid collections in 148 consecutive patients. *Journal of gastroenterology and hepatology*. 2011 Oct;26(10):1504-1508.