

Iatrogenic Vas Deferens Injuries: Neglected Infertility Causing TraumasAli Shalizar Jalali^{1,*}¹Department of Basic Sciences, Faculty of Veterinary Medicine, Urmia University, Urmia, Iran

Received: 22 May 2017

Accepted: 15 Jun 2017

Medical or surgical related fertility impairments are called iatrogenic infertilities and contribute to nearly 5% of infertilities both in men and women (1, 2). Iatrogenic vas deferens injuries (IVDIs) as inadvertently medical conditions are critical complications of surgical operations in the inguinal region of children and adults (3). Inguinal herniorrhaphy, one of the most common therapies carried out worldwide by general and/or pediatric surgeons, is executed through using open, laparoscopic or pre-peritoneal approaches (4) and transection or ligation induced injuries account for about 25% of iatrogenic vas deferens damages (5). Moreover, accidental crushing of inguinal contents leading to unpredictable consequences is also unavoidable (6).

It is well documented that any scant disturbance in vas deferens tunica muscularis or mucosa will endanger fertility and unintentionally manipulations during inguinal hernia repair can cause perforation and/or obstruction of damaged vas deferens resulting in male fertility reduction (7, 8). It was found that vas deferens surgical manipulations such as grasping with toothed and/or non-toothed forceps, clamping with mosquito hemostats and electrocoagulation can induce histoarchitectural changes including intra- and transmural inflammatory reactions, mural and muscular wall disorganization and luminal destruction (4). Moreover, it is worth mentioning that vas deferens obstruction brings about testicular blood flow disturbance and finally testicular hypoxia along with atrophy (9). It has also been suggested that IVDIs can play crucial roles in formation of anti-sperm autoantibodies and sympathetic vasospasm leading to bilateral testicular deterioration as well as sperm

motility and capacitation impairments (10-12). Recently, it has been reported that experimental unilateral IVDIs have injurious bilateral effects on epididymal sperm characteristics and in vitro fertilizing potential leading to early developmental arrests (13-15).

In line with that, it seems that non-recognized IVDIs may have destructive effects on spermatogenesis resulting in fertility problems (Fig. 1) and careful attention to surgical detail should be considered during inguinal region surgical procedures to prevent IVDIs. However, recent progresses in urological microsurgeries and assisted reproductive technologies provide remarkable improvements in fertility outcomes of patients even with serious iatrogenic reduction in fertility (16).

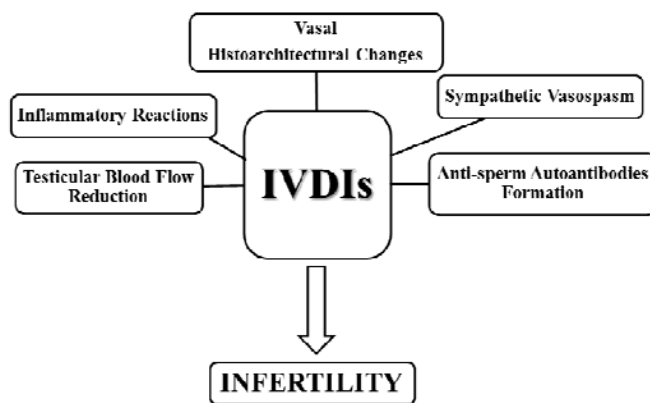


Fig. 1. Pathophysiology diagram of iatrogenic vas deferens injuries (IVDIs) induced infertility

References

1. Kuku SF, Oseghe DN. Oligo/azoospermia in Nigeria. *Arch Androl.* 1989; 22(3): 233-238.
2. Nudell DM, Monoski MM, Lipshultz LI. Common medications and drugs: how they affect male fertility. *Urol Clin North Am.* 2002; 29(4): 965-973.
3. Antypas S, Sofikitis N, Rodriguez F, Zavos PM, Miyagawa I. Bilateral effect of unilateral vasectomy on testicular testosterone biosynthesis. *J Pediatr Surg.* 1994; 29(6): 828-831.
4. Blouchos K, Boulas K, Tselios D, Hatzigeorgiadis A, Kirtsis P. Iatrogenic vas deferens injury due to inguinal hernia repair. *Hell J Surg.* 2012; 84(6): 356-363.
5. Schlegel PN. Causes of azoospermia and their management. *Reprod Fertil Dev.* 2004; 16(5): 561-572.
6. Abasiyanik A, Guvenc H, Yavuzer D, Peker O, Ince U. The effect of iatrogenic vas deferens injury on fertility in an experimental rat model. *J Pediatr Surg.* 1997; 32(8): 1144-1146.
7. Ridgway PF, Shah J, Darzi AW. Male genital tract injuries after contemporary inguinal hernia repair. *BJU Int.* 2002; 90(3): 272-276.
8. Sandhu DP, Osborn DE. Surgical technique for inguinal surgery and its effect on fertility in the Wistar rat model. *Br J Urol.* 1991; 68(5): 513-517.
9. Pampal A, Ozen IO, Ekingen G, Demirogullari B, Helvacioğlu F, Take G. The morphological evaluation of ipsilateral and contralateral vasa deferentia in a rat model of unilateral spermatic cord torsion. *Pediatr Surg Int.* 2010; 26(3): 287-292.
10. Chehval MJ, Martin SA, Alexander NJ, Winkelmann T. The effect of unilateral injury to the vas deferens on the contralateral testis in immature and adult rats. *J Urol.* 1995; 153(4): 1313-1315.
11. Hendry WF, Hughes L, Scammell G, Pryor JP, Hargreave TB. Comparison of prednisolone and placebo in subfertile men with antibodies to spermatozoa. *Lancet.* 1990; 335(8681): 85-88.
12. Kutlu O, Kocabiyik A, Koksall IT, Guntekin E. Effects of chemical sympathectomy on contralateral testicular histology and fertility in unilateral vasectomy. *J Korean Med Sci.* 2009; 24(5): 849-852.
13. Babaei M, Shalizar Jalali A, Najafi G, Behfar M. Evaluation of epididymal necrospermia following experimental unilateral iatrogenic vas deferens injury in mouse. *Iran J Immunol.* 2014; 11(1): 406.
14. Babaei M, Najafi G, Shalizar Jalali A, Behfar M, Esmaili Gouvarchin Ghaleh H. Unilateral iatrogenic vas deferens injury induces apoptosis in mouse spermatozoa. *Iran J Immunol.* 2014; 11(1): 406-407.
15. Babaei M, Najafi G, Shalizar Jalali A, Behfar M. Effects of unilateral iatrogenic vas deferens trauma on fertility: an experimental in vitro fertilization mice model study. *Bull Emerg Trauma.* 2015; 3(4): 122-127.
16. Lee SJ, Schover LR, Partridge AH, Patrizio P, Wallace WH, Hagerty K, Beck LN, Brennan LV, Oktay K. American Society of Clinical Oncology recommendations on fertility preservation in cancer patients. *J Clin Oncol.* 2006; 24(18): 2917-2931.