

## Exploring the rare: A case report and literature review on cotyledonoid dissecting leiomyoma

Alka Yadav<sup>1,\*</sup>, Sujata Raychaudhuri<sup>2</sup>, Lakshinder Kaur<sup>2</sup>, Minakshi Bhardwaj<sup>2</sup>

<sup>1</sup> Department of Pathology, Uttar Pradesh University of Medical Sciences Saifai, India

<sup>2</sup> Department of Pathology, ESIC Medical College and Hospital Faridabad, India

Received: 23 Jan 2024 Accepted: 2 April 2024

### Abstract

Leiomyomas, benign smooth muscle tumors of the uterus, commonly present with bleeding and are known for their varied morphology. This case report highlights a rare variant, Cotyledonoid dissecting leiomyoma, which poses diagnostic challenges due to its unusual appearance and growth pattern, often mimicking malignancy.

We present the case of a 65-year-old female with clinical symptoms of pain, urinary retention, and bleeding, who underwent total abdominal hysterectomy. Gross examination revealed a large mass with lobulated patterns, raising concerns for malignancy. Microscopic examination, however, revealed characteristic features of Cotyledonoid dissecting leiomyoma, including nodular growth and dissection within the myometrium without atypical or mitosis.

Our literature review identified only 28 reported cases of this variant, emphasizing its rarity and diagnostic importance. Clinicians and pathologists must be aware of this entity to avoid unnecessary overtreatment.

Frozen sections may aid in accurate diagnosis, particularly to preserve fertility in young women. While leiomyomas are predominantly conventional, rare subtypes like Cotyledonoid dissecting leiomyoma warrant recognition to prevent misdiagnosis and ensure appropriate management. This case underscores the importance of histopathological evaluation in guiding clinical decisions for patients with unusual uterine tumors.

**Keywords:** Cotyledonoid dissecting leiomyoma, Histopathological evaluation, Leiomyomas, Uterine tumors

### Introduction

Leiomyomas are prevalent benign mesenchymal tumors originating from smooth muscle cells. They typically share a consistent gross appearance, characterized by a well-circumscribed, tan-white, whorled surface. Microscopically, conventional leiomyomas exhibit spindle-shaped smooth muscle cells arranged in fascicles with a whorled pattern. However, among the spectrum of leiomyomas, cotyledonoid dissecting leiomyoma stands out as a rare variant.

First delineated by Roth et al. in 1996, this variant presents unique challenges due to its gross and radiologic features, often suggestive of malignancy (1). Despite its rarity, cotyledonoid dissecting leiomyomas are notably predominant among uterine tumors, affecting approximately 70% of premenopausal women and showing a higher incidence in women of African descent (2).

While the gross appearance of cotyledonoid dissecting leiomyomas may raise concerns for malignancy, it's essential to differentiate them from

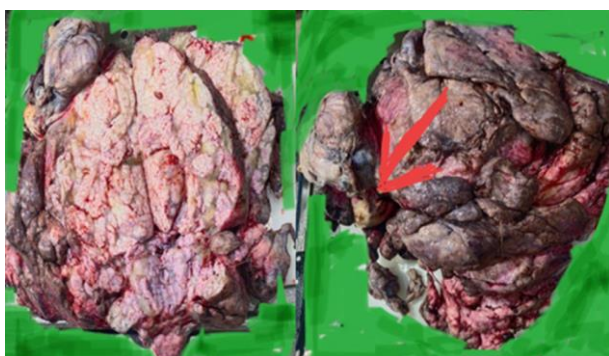\*Correspondence author: Alka Yadav, Department of Pathology, Uttar Pradesh University of Medical Sciences Saifai, India

leiomyosarcomas. Unlike the latter, cotyledonoid dissecting leiomyomas lack key features such as increased mitotic activity, cellular atypia, and coagulative tumor necrosis (1,3). Herein, we present a case of cotyledonoid dissecting leiomyoma in a perimenopausal female, manifesting with symptoms including urinary retention, abdominal pain, and anemia, underscoring the importance of accurate diagnosis and management of this rare subtype.

## Case Report

A 45-year-old female presented to the gynecology department with a 15-day history of abdominal pain and one month of urinary retention. Upon vaginal examination, a bulky uterus was noted. Ultrasound imaging revealed a large predominantly solid adnexal mass with increased vascularity extending throughout the left abdomen, along with diffuse omental thickening. Subsequently, a total abdominal hysterectomy (TAH) with bilateral salpingo-oophorectomy (BSO) was performed, and the specimen was sent for histo-pathological examination.

Gross examination revealed a uterus with cervix and attached bilateral adnexa measuring 9x6.5x3 cm, accompanied by a large mass attached to the uterus measuring 43x35x10 cm. The endocervical canal measured 2.8 cm, while the endometrium measured 0.2 cm. The myometrial thickness varied from 2 to 17 cm, displaying irregular grey-white to grey-brown cotyledons upon serial sectioning (Figure 1).

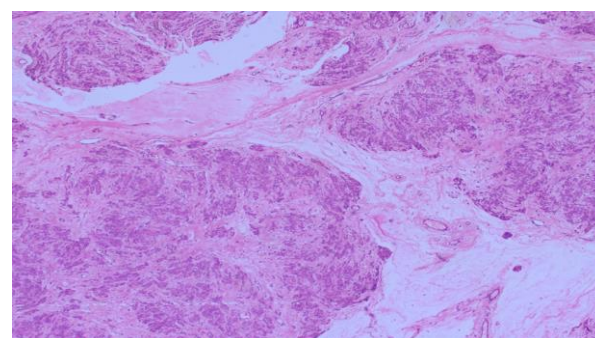


**Figure 1.** Illustrates the gross specimen of the uterus with cervix, showcasing the attachment of a prominent adnexal cotyledonoid mass, reminiscent of a placental-like appearance.

The right and left ovaries measured 2.3x1.3x1 cm and 2.5x2x1 cm, respectively, with smooth outer surfaces and partly solid, partly cystic contents filled

with blood clot. The right and left fallopian tubes measured 3.5 cm and 3 cm, respectively, with visible lumens.

Serum levels of CA 125 were recorded at 47.3. Microscopic examination revealed tumor cells arranged in variable-sized nodules, clusters, cords, and



singly scattered formations (Figure 2).

**Figure 2.** Depicts tumor cells arranged in variable-sized nodules, clusters, and cords. These cells exhibit a diverse morphology, ranging from plump, round to polygonal, and spindle-shaped, with round to oval nuclei, vesicular chromatin, inconspicuous nucleoli, and a moderate amount of eosinophilic cytoplasm. Notably, the tumor is observed dissecting between smooth muscle bundles of the myometrium.

These cells exhibited plump, round to polygonal, and spindle shapes, with round to oval nuclei, vesicular chromatin, inconspicuous nucleoli, and a moderate amount of eosinophilic cytoplasm. Notably, the tumor was observed dissecting between smooth muscle bundles of the myometrium, with stroma displaying marked edema, cystic changes, myxoid alterations, and numerous thick-walled blood vessels.

However, no atypia, mitosis, or necrosis was evident in the examined sections. The final diagnosis was established as Dissecting Cotyledonoid Leiomyoma, which in this case was associated with multiple intramural leiomyomas. Furthermore, the endometrium exhibited proliferative changes, while the cervix displayed features consistent with chronic ectoendocervicitis.

## Discussion

Dissecting leiomyoma represents a rare and distinctive variant of leiomyoma, presenting a diagnostic conundrum for clinicians, radiologists, and pathologists, often leading to confusion with malignant uterine neoplasms. Despite its significance, only a

handful of cases have been documented in the medical literature.

The index case also manifested with lower abdominal pain, though notably lacked vaginal bleeding. Tumor sizes typically ranged from 2 to 15 cm (4, 5). Three distinct types of Cotyledonoid dissecting leiomyoma (CDL) have been delineated. The first type presents as an exophytic mass of multinodular tissue protruding from the lateral surface of the uterine cornua, bearing a striking resemblance to the placenta, hence termed CDL. The second type involves an intramural dissecting tumor confined within the uterus, sharing similar histopathological features with the former. Lastly, the pure Cotyledonoid leiomyoma represents the third type, devoid of association with either a parent intramural mass or intramural dissection (6). In our case, the presentation aligned with the exophytic type.

Microscopically, CDL exhibits characteristic features, including nodules of uniform smooth muscles arranged in interlacing and whorling fascicles, often accompanied by prominent blood vessels and focal hypercellular areas. Crucially, the absence of mitotic activity, nuclear atypia, cellular pleomorphism, and necrosis distinguishes it from malignant lesions. Furthermore, CDL typically lacks vascular invasion, capsular infiltration, or metastasis, although perinodular hydropic changes may occasionally be notable (7).

Notably, Gurbuz et al. (8) documented a unique case of Cotyledonoid leiomyoma displaying extrauterine extensions despite lacking an intrauterine portion. For a comprehensive understanding, a comparative analysis of various CDL cases reported in the literature is provided in Table.

**Table 1.** Summary of the published cases of Cotyledonoid dissecting leiomyoma

SN	Reference	Age	Clinical presentation	Tumor size (cm) maximum dimension	Tumor location
1	David et al. (1)	65	Abnormal uterine bleed	15	Uterine fundus and cervix
		48	Uterine prolapse	12	Uterine fundus
2	Roth et al. (2)	39	Pelvic mass	10.3	Uterine cornua
		41	Abnormal uterine bleed	10	Uterine cornua
		23	Pelvic mass	25	Uterine cornua
		Unknown	Pelvic mass	24	Uterine cornua
3	Brand et al. (3)	24	Abdominal mass	NA	Uterine fundus
4	Roth and Reed (4)	46	Pelvic mass	34	Uterine cornua
5	Kim et al. (5)	26	Incidental	12	Posterior uterine wall
6	Cheuk et al. (6)	55	Abnormal uterine bleed	10	Uterine cornua
7	Stewart et al. (7)	58	Abdominopelvic mass	16.4	Uterine fundus
8	Jordan et al. (8)	46	Right adnexal mass	22	Uterine with extrauterine extension (all cases)
9	Saeed et al. (9)	27	Pelvic mass	41	Uterine fundus
10	Maimoon et al. (10)	40	Urinary retention	10	Uterine isthmus
11	Shelekhova et al. (11)	73	Uterine mass	8	Uterine fundus
12.	Gurbazet.al. (12)	67	Incidental	10	Uterine cornua

SN	Reference	Age	Clinical presentation	Tumor size (cm) maximum dimension	Tumor location
13	Weissferdt et al. (13)	52	Abnormal uterine bleed	6.2	Uterine fundus
14	Present case	45	Urinary retention, Pain in abdomen	43	Uterine lateral wall

## Conclusion

Our case highlights the importance of recognizing rare leiomyoma variants in uterine tumor diagnosis, especially with unusual clinical and radiological findings. Accurate differentiation from malignant neoplasms is crucial for proper management. Microscopic examination is key, revealing distinct histopathological features. Further research is needed to better understand and manage dissecting Cotyledonoid leiomyomas, emphasizing collaboration among medical disciplines.

## Acknowledgements

We would like to express our gratitude to the patients and their families who have participated in medical research and have contributed to the advancement of medical knowledge and understanding. Their participation and trust in the medical community are essential to the progress of medical research and education.

## Conflicts of Interest

We have no commercial or financial gains for this study.

## References

- Roth LM, Reed RJ, Sternberg WH. Cotyledonoid dissecting leiomyoma of the uterus. The Sternberg tumor. Roth LM, Reed RJ, Sternberg WH. <https://doi.org/10.1097/00000478-199612000-00004>. Am J Surg Pathol 1996; 20: 1455–1461.
- Stewart EA, Cookson CL, Gandolfo RA, Schulze-Rath R. Epidemiology of uterine fibroids: a systematic review. Stewart EA, Cookson CL, Gandolfo RA, Schulze-Rath R BJOG 2017; 124: 1501–1512.
- Meena LN, Aggarwal A, Jain S. Cotyledonoid leiomyoma of uterus. Meena LN, Aggarwal A, Jain S. J Obstet Gynaecol India 2014; 64: 146–147.
- Menolascino-Bratta F, García de Barriola V, Naranjo de Gómez M, et al. Cotyledonoid dissecting leiomyoma (Sternberg tumor): an unusual form of leiomyoma Pathol Res Pract 1999; 195: 435–438.
- Smith CC, Gold MA, Wile G, Fadare O. Cotyledonoid dissecting leiomyoma of the uterus: a review of clinical, pathological, and radiological features. Int J Surg Pathol 2012; 20: 330–341.
- Cramer SF, Patel A. The frequency of uterine leiomyomas. Am J Clin Pathol 1990; 94: 435–438.
- Tanaka H, Toriyabe K, Senda T, et al. Cotyledonoid dissecting leiomyoma treated by laparoscopic surgery: a case report. Asian J Endosc Surg 2013; 6: 122–125.
- Gurbuz A, Karateke A, Kabaca C, Arik H, Bilgic R. A case of cotyledonoid leiomyoma and review of the literature. Int J Gynecol Cancer 2005; 15: 1218–1221.
- Saeed AS, Hanaa B, Faisal AS, Najla AM. Cotyledonoid dissecting leiomyoma of the uterus. A case report of benign uterine tumour with sarcoma like gross appearance and review of literature. Int J Gynecol Pathol 2006; 25 (3): p262–267.
- Maimoon S, Wilkinson A, Mahore S, Bothale K, Patrikar A. Cotyledonoid leiomyoma of the uterus. Indian J Pathol Microbiol 2006; 49(2): 289–291.
- Shelekhova KV, Kazakov DV, Michal M. Cotyledonoid dissecting leiomyoma of the uterus with intravascular growth: report of two cases. Virchows Arch 2007; 450(1): 119–121.
- Gurbuz A, Karateke A, Kabaca C, Arik H, Bilgic R. A case of cotyledonoid leiomyoma and review of the literature. Int J Gynecol Cancer 2005; 15(6): 1218–1221.
- Weissferdt A, Maheshwari MB, Downey GP, Rollason TP, Ganesan R. Cotyledonoid dissecting leiomyoma of the uterus: a case report. Diagn Pathol 2007; 2:18.