

Vaginal wall cysts in a prepubertal girl: a case report

Zahra Basirat ^{1,*}, Masoumeh Golsorkhtabaramiri ²

¹Infertility and Reproductive Health Research Center, Health Research Institute & Clinical Research Development Unit of Rouhani Hospital & Department of Obstetrics and Gynecology, Babol University of Medical Science, Babol Iran

²Infertility and Reproductive Health Research Center, Health Research Institute, Babol University of Medical Science, Babol, Iran

Received: 23 May 2015

Accepted: 24 Jun 2015

Abstract

A vaginal cyst is an encapsulated sac, situated on or under the lining of vagina, and contains liquid or semi liquid substance. Vaginal cysts have rarely proved to be more troublesome than causing a bit of discomfort and slight pain, but in some cases, they can develop into tumors. A 5-year-old girl, who was complaining about a weird pain in her lower abdomen, was referred to the gynecology center of the hospital. Ultrasonography revealed a vague large cyst in her uterus and vagina. Surgical procedure was necessary to remove it. The patient was followed up for 6 months, and no sign of recurrence of the cyst was observed.

Keywords: Cyst, Vagina, Prepubertal girl

Introduction

A vaginal cyst occurs when a clogged duct or gland is on or under the vaginal lining, which collects fluid or semisolid material. It may be an embryological or urogenital abnormality or an ectopic tissue. Vaginal cysts are scarce. They are most common during the third and fourth decades of life, and are rarely found in pubertal females. It may cause a variety of symptoms including pain, dyspareunia, bleeding, sense of vaginal pressure, and voiding discomfort (1, 2, 3, 4). They may be totally painless, and can usually palpate incidentally on gynecological examination (1). This case report elaborates on our experience to manage a vaginal wall cyst in a little girl.

Case Report

The patient was a five-year-old girl, who was complaining about a strange pain in her lower abdomen, referred to our gynecology center. Her parents did not report any background of pelvic

infection, trauma or surgery for her. In the clinical examination, the hymen was prominent outward and a mass was palpated in the right lateral wall of the vagina. In addition, no sign of precocious puberty was seen. In the initial ultrasonography of the lower abdomen, the right kidney was not seen and the left kidney seemed enlarged. Both ovaries were small with prepubertal presentation. No image of normal uterus was seen, and two elongate echo-free cysts, which were along each other, were observed instead. The sizes of the cysts were 56.33 mm and 19.10 mm, which are shown in Figure 1. Fluid retention was seen in both vagina and uterus, and the findings show that the hymen was imperforated. Despite the fact that only one kidney had been observed, no other paraaortic lymphadenopathy or genitourinary abnormalities were observed. According to MRI report, the fluid collection in the endometrial cavity of the uterus and the cervical canal was compatible with hematocolpometra.

According to the results of the laboratory tests, cancer markers like CA125 and alpha feto protein test,

*Corresponding author: Dr. Zahra Basirat, Infertility and Reproductive Health Research Center, Babol University of Medical Science, Babol, Iran. Telefax: +98-11-32274880-2, Email: basiratzahra@yahoo.com

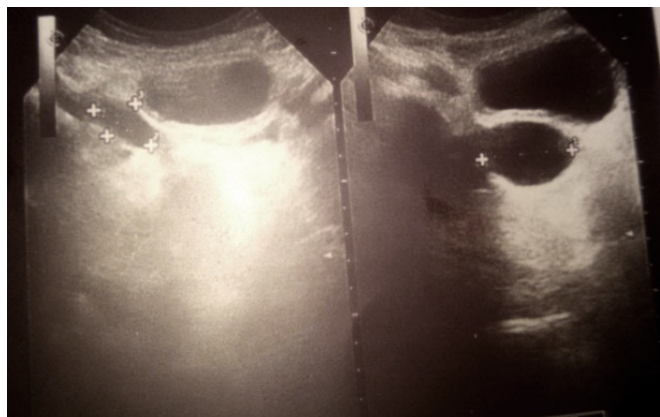


Fig. 1: Ultrasonography of the lower abdomen showing two elongate echo-free cysts (56.33 mm and 19.10 mm)

other routine tests (complete blood count, fasting blood Sugar, ...), and hormonal assay (FSH, LH, TSH) were all in normal limits.

In the operating room, we put the patient in a lithotomy position and observed a normal hymeneal ring with a bruise swelling in the right side of the vagina wall. We made a 1cm vertical incision there, and 30cc of transparent colorless mucinous discharge was evacuated. We inserted a catheter, which was as long as the vagina (7-8 cm), into the incision, and drained all the fluid through it. In addition, a rectal examination was performed to ensure all fluid had been evacuated. We did not repair the site to extract the probable leakage in the subsequent days. After 6 days, the incision site went dry and repaired spontaneously. According to the findings of the postoperative ultrasonography, uterus, with cervical prominancy, and the vagina dimension was totally normal. No previous suspicious cyst was observed.

Discussion

The type of vaginal wall cysts will determine the cause of its formation, prognosis and incidence. Vaginal cysts are rarely found in pre-pubertal children. The process carries a slight danger of complications, based on where the cyst is situated in relation to other

nearby structures. According to a study on forty cases of benign vaginal cysts, 12 cases were mullerian cysts, 11 cases were bartholin's duct cysts, ten cases were epidermal inclusion cysts, five cases were Gartner's duct cysts, one case was endometrioid cyst, and another one was an unclassified cyst (4). In addition, being familiar with various diagnoses of benign cysts of the vagina and their abnormalities will definitely help us with the diagnosis and treatment of them (5). MRI and ultrasound are helpful methods, which can reveal the localization, the number, and the communication of these cysts with adjacent tissues (6). In our case, the cyst was large enough to cause symptoms; therefore, we decided to perform surgical management to remove it.

References

1. Hwang JH, Oh MJ, Lee NW, Hur JY, Lee KW, Lee JK. Multiple vaginal mullerian cysts: a case report and review of literature. *Arch Gynecol Obstet* 2009; 280(1):137-139.
2. Rivlin ME, Meeks GR, Ghafar MA, Lewin JR. Intracystic hemorrhage in a non-endometriotic mullerian vaginal cyst. *World J Clin Cases* 2013; 1(1):34-36.
3. Sreelatha S, Ashok Kumar, Anitha GS, Tejaswini BH. An unusual case of posterior vaginal wall cyst. *Int J Reprod Contracept Obstet Gynecol* 2014; 3(1): 282-284
4. Lang ME, Darwish A, Long AM. Vaginal bleeding in the prepubertal child. *CMAJ* 2005;172(10):1289-1290.
5. Eilber KS, Raz S. Benign cystic lesions of the vagina: a literature review. *J Urol.* 2003; 170(3):717-722.
6. Portnoy OI, Kitrey N, Eshed I, Apter S, Amitai MM, Golomb J. Correlation between MRI and double-balloon urethrography findings in the diagnosis of female periurethral lesions. *Eur J Radiol* 2013; 82(12):2183-2188.