10.22088/caspjrm.12.1.43

Caspian J Reprod Med, 2026, 12 (1): 43-47

Caspian Journal of Reproductive Medicine

Journal homepage: www.caspjrm.ir

Case report

Placenta increta presenting with postpartum fever and hemorrhage in an unscarred uterus: A case report

Shabnam Mehdinia [1], Mina Galeshi [1], Zeynab Mohseni Afshar [1], Soheila Abbaszadeh[1, *]

[1] Clinical Research Development Unite of Rouhani Hospital, Babol University of Medical Sciences, Babol, Iran

Received: 16 May 2026 Accepted: 25 Jun 2026

Abstract

Background: Placenta accreta spectrum (PAS) is characterized by abnormal placental adherence or invasion into the uterine wall and is usually associated with previous cesarean delivery. Postpartum fever is a rare presentation and may mimic infection or retained products of conception. We report a rare case of placenta increta presenting with persistent postpartum fever after vaginal delivery.

Case Presentation: A 37-year-old woman presented six days after spontaneous vaginal delivery at 36 weeks with persistent fever. Delivery had been complicated by premature rupture of membranes and significant postpartum hemorrhage, followed by suction curettage for suspected retained placental tissue. She subsequently developed recurrent fever and persistent abnormal intrauterine findings on ultrasonography. On admission, she had uterine tenderness, leukocytosis, and markedly elevated inflammatory markers. Despite broad-spectrum antibiotics, repeat ultrasonography suggested retained products of conception. A second curettage failed to completely remove the tissue. Color Doppler ultrasonography demonstrated bridging vessels and retroplacental lacunae with turbulent flow, suggesting placental invasion. Bilateral uterine artery embolization was performed, and histopathology confirmed chorionic villi invading the myometrium, consistent with placenta increta. Her clinical condition subsequently improved.

Conclusion: PAS should be considered when presumed retained placental tissue cannot be completely removed, particularly in the presence of abnormal Doppler vascularity, even after vaginal delivery without a previous cesarean section. Early recognition may prevent repeated invasive procedures and serious maternal complications.

Keywords: Fever, Placenta increta, Postpartum

[Downloaded from caspjrm.ir on 2026-11-25]

[DOI: 10.22088/caspjrm.12.1.43]

***Correspondence author:** Dr. Soheila Abbaszadeh, **ORCHID ID**: https://orcid.org /0009-0002-7697-607X, **Email**: dr.abbaszadeh@gmail.com

This work is licensed under a Creative Commons Attribution-NonCommercial 4.0International License.
Copyright © 2020 Iranian Caspian Journal of Reproductive Medicine, and Babol University of Medical Sciences.

Introduction

Postpartum fever is characterized by two measurements of body temperature greater than 38.0°C at least 6 hours apart during the first 10 days after delivery, excluding the first 24 hours. It may occur after either vaginal delivery or cesarean section and is commonly associated with endometritis, infection at the cesarean incision or episiotomy site, mastitis, urinary tract infection, and septic pelvic thrombophlebitis (1). Retained products of conception (RPOC) should also be considered, particularly when fever is accompanied by vaginal bleeding, uterine enlargement or tenderness, and pelvic pain (2, 3).

Placenta accreta spectrum (PAS) includes placenta accreta, placenta increta, and placenta percreta, which result from abnormal placental adherence and invasion of the uterine wall. Although previous cesarean delivery is a major risk factor, PAS may also occur in association with multiparity, advanced maternal age, myomectomy, hysteroscopy, and uterine curettage (4).

Recent literature has also documented PAS in patients without prior cesarean delivery, supporting the possibility of this uncommon presentation (5). PAS is typically associated with retained placenta and severe postpartum hemorrhage (6); however, postpartum fever may rarely be its presenting feature (5). Because delayed diagnosis can result in hemorrhage, infection, sepsis, emergency hysterectomy, and maternal death, early recognition and timely multidisciplinary management are essential priorities in reducing preventable maternal morbidity and mortality.

We present a rare case of placenta increta following vaginal delivery of a healthy newborn in a woman who was admitted to the hospital with postpartum fever. This case highlights the importance of considering PAS in the differential diagnosis of persistent postpartum fever, even in the absence of previous cesarean delivery or antenatal suspicion.

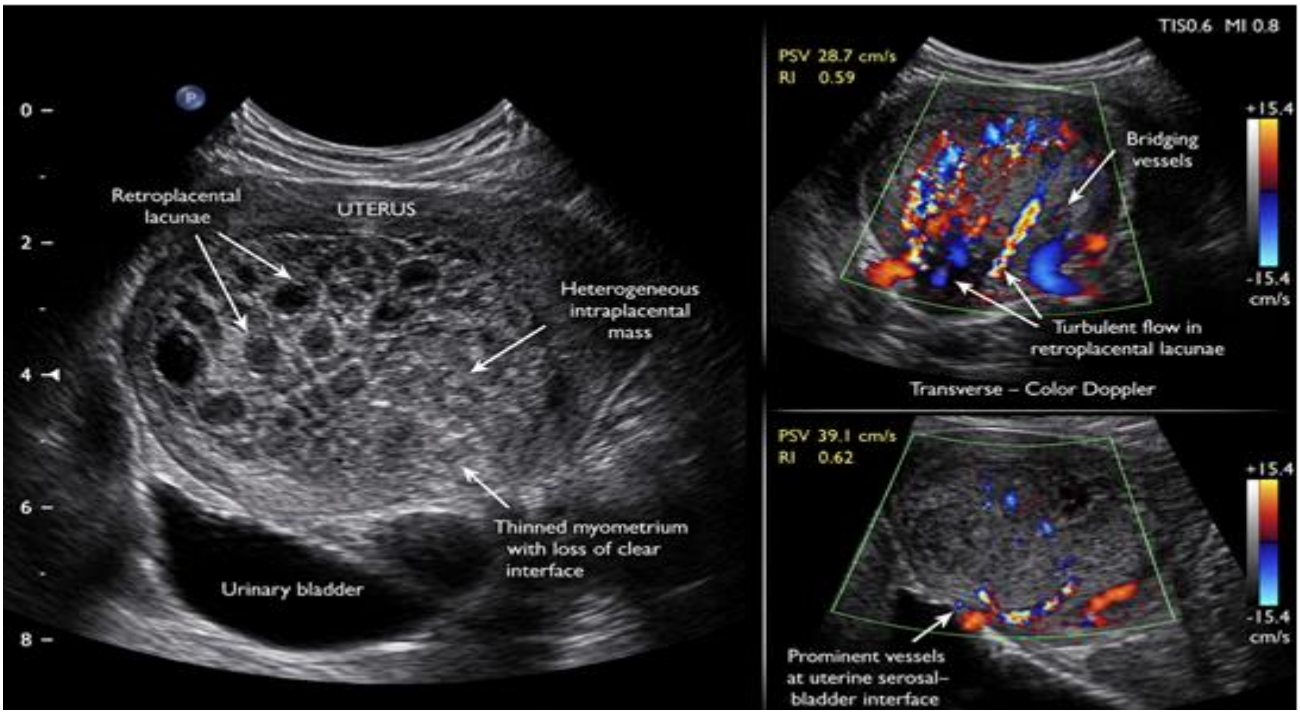

Figure 1. Grayscale and color Doppler ultrasound images from the present case illustrating the sonographic features of placenta increta, including retroplacental lacunae with turbulent blood flow, bridging vessels, and decreased visualization of the uterine serosal–bladder interface, consistent with myometrial invasion.

Case presentation

A 37-year-old woman presented with postpartum fever six days after a spontaneous vaginal delivery at 36 weeks of gestation. The pregnancy had been complicated by premature rupture of membranes. The delivery was followed by significant postpartum hemorrhage, and suction curettage was performed because retained placental tissue was suspected. She was subsequently discharged with advice to undergo follow-up ultrasonography within one week.

During the post-discharge follow-up period, ultrasonography revealed an inhomogeneous intrauterine echo suggestive of retained products of conception. She subsequently experienced two further episodes of fever. In view of the persistent postpartum

[Downloaded from caspjrm.ir on 2026-11-25]

[DOI: 10.22088/caspjrm.12.1.43]

fever and abnormal ultrasonographic findings, she was referred to our center for further assessment and evaluation for possible abnormal placentation.

On admission, she was febrile and reported hypogastric and right lateral uterine tenderness. Laboratory investigations showed leukocytosis, with a white blood cell count of 15,400/µL, and elevated inflammatory markers, including a C-reactive protein level of 145 mg/L, erythrocyte sedimentation rate of 95 mm/h, and procalcitonin level of 32 ng/mL. Empirical antimicrobial therapy was initiated with clindamycin, gentamicin, and ampicillin. Following consultation with the infectious diseases team, treatment was modified to gentamicin, meropenem, and vancomycin.

Repeat ultrasonography again demonstrated findings suggestive of retained products of conception, and a second curettage was performed. However, the placental tissue could not be completely removed. Given the incomplete removal and the possibility of abnormal placental invasion, color Doppler ultrasonography was performed. It demonstrated bridging vessels, retroplacental lacunae with turbulent blood flow, and poor visualization of the uterine serosal–bladder interface and retroplacental arteries. These findings were consistent with placental invasion into the myometrium and supported a diagnosis of placenta increta (Figure 1).

The patient subsequently underwent bilateral uterine artery embolization under fluoroscopic guidance. Post-embolization angiography confirmed successful occlusion of the uterine arterial blood flow. Histopathological examination of the retrieved placental tissue demonstrated chorionic villi extending into the myometrium, confirming the diagnosis of placenta increta.

Following embolization, the patient's fever and leukocytosis resolved, and her clinical condition improved. She was discharged one day after the procedure with oral ciprofloxacin and metronidazole. At the one-week follow-up visit, ultrasonography showed no evidence of residual vascularity, and the patient remained clinically well.

Discussion

This case is unusual because placenta increta was diagnosed after a normal vaginal delivery at 36 weeks in a patient with no recorded history of previous cesarean delivery. While a prior cesarean is the strongest known risk factor for PAS, the condition can still occur in women without any cesarean scar. Other reported risk factors include advanced maternal age, multiparity, previous uterine surgery or curettage, and Asherman syndrome (7). The occurrence of PAS in the absence of a previous cesarean delivery therefore does not exclude the diagnosis and highlights the importance of considering other forms of endometrial–myometrial interface disruption (8). Recent case literature has similarly documented PAS in patients without previous cesarean delivery, supporting the possibility of this uncommon presentation (9).

The absence of a previous cesarean delivery in our patient is particularly relevant because the most widely accepted pathophysiological model of PAS involves abnormal placental implantation at an area of defective decasualization, frequently associated with a uterine scar (10). However, this model does not fully explain all cases occurring in women without previous uterine surgery or cesarean delivery. American College of Obstetricians and Gynecologists (ACOG) notes that disruption of the uterine cavity, including prior curettage or other uterine instrumentation, may also damage the endometrial–myometrial interface and contribute to abnormal placental implantation (11). Prior uterine instrumentation, including curettage, is a recognized (though not absolute) risk factor for PAS and should be considered in the differential diagnosis even in the absence of cesarean delivery. In the present case, however, the available information does not establish that the curettage performed after delivery caused the abnormal placental invasion. Rather, the curettage was performed because placental remnants were already suspected following significant postpartum hemorrhage. Thus, the temporal relationship should be interpreted cautiously, and curettage should not be considered the proven cause of placenta increta in this patient.

The role of curettage is nevertheless an important feature of this case. The patient initially underwent suction and curettage for suspected retained placental tissue after significant postpartum hemorrhage. Follow-up ultrasonography continued to demonstrate an intrauterine abnormality suggestive of retained products of conception, leading to repeat curettage at our center. The placental tissue could not be completely removed. In retrospect, the failure to remove the tissue completely was an important clinical clue that the abnormal tissue might represent abnormally adherent or invasive placenta rather than uncomplicated RPOC. Pathology recommendations for PAS specifically recognize curetting obtained for presumed retained products of conception as specimens in which invasive placentation may be encountered (12).

This distinction is clinically important because attempts to remove abnormally adherent placental tissue can result in substantial hemorrhage. ACOG recommends avoiding forced placental removal when PAS is suspected because disruption of the abnormal placental attachment can lead to severe hemorrhage (13). In the present case, PAS was not initially recognized and the patient was managed under the working diagnosis of RPOC. The subsequent Doppler

[Downloaded from caspjrm.ir on 2026-11-25]

[DOI: 10.22088/caspjrm.12.1.43]

findings changed the diagnostic interpretation and led to recognition of placenta increta before further attempts at removal.

Another distinctive aspect of this case was the coexistence of persistent postpartum fever, uterine tenderness, and markedly elevated inflammatory markers with persistent intrauterine placental tissue. The patient initially received antimicrobial therapy, which was subsequently escalated following infectious diseases consultation because of persistent fever and significant inflammatory abnormalities. However, the persistence of intrauterine tissue despite antimicrobial treatment suggested that infection alone did not adequately explain the clinical presentation. This illustrates the diagnostic challenge of postpartum PAS when the clinical picture overlaps with retained products of conception and postpartum infection. Zhong et al. (2017) previously reported a series of patients with placenta accreta associated with fever following vaginal delivery and recommended conservative management strategies including antibiotics, interventional therapy, and selective ultrasound-guided curettage. Our case is consistent with this earlier experience and further emphasizes the value of color Doppler assessment when complete removal of presumed RPOC is not possible (5).

Color Doppler ultrasonography subsequently provided important evidence of abnormal placental vascularity and myometrial invasion. The presence of retroplacental lacunae and turbulent blood flow is among the sonographic findings associated with PAS, although individual ultrasound features cannot reliably determine the exact depth of invasion (14). In our patient, bridging vessels, retroplacental lacunae with turbulent blood flow, and decreased visualization of the uterine serosal–bladder interface and retroplacental arteries increased the suspicion of myometrial invasion. This imaging assessment was particularly important after unsuccessful curettage and prompted a change in management.

The diagnosis was subsequently supported by histopathological examination demonstrating chorionic villi extending into the myometrium, consistent with placenta increta. The combination of the clinical course, Doppler findings, failure of complete removal of the placental tissue, and histopathological evidence provided complementary evidence for the diagnosis.

Overall, this case emphasizes that placenta increta should remain in the differential diagnosis of persistent postpartum intrauterine placental tissue even after vaginal delivery and in the absence of a documented previous cesarean delivery. The difficulty in removing presumed RPOC should raise suspicion for abnormal placental adherence, particularly when Doppler examination demonstrates marked retroplacental vascularity. Early recognition of this possibility may help avoid repeated attempts at placental removal and facilitate timely multidisciplinary management.

Conclusion

This case highlights the diagnostic challenge of placenta accreta spectrum, specifically placenta increta, presenting in the postpartum period after a normal vaginal delivery and without a documented history of previous cesarean delivery. The coexistence of persistent postpartum fever, presumed retained products of conception, and abnormal placental vascularity initially complicated the diagnosis. Failure to completely remove the suspected retained placental tissue, followed by characteristic color Doppler findings, prompted consideration of abnormal placental invasion and ultimately led to the diagnosis of placenta increta. This case emphasizes that placenta accreta spectrum should be considered even after vaginal delivery when placental tissue cannot be completely removed and abnormal vascularity is present. Timely recognition with appropriate imaging and multidisciplinary management, including uterine artery embolization when clinically appropriate, may help prevent severe maternal morbidity.

Acknowledgements

This research was conducted in accordance with the ethical principles outlined in the Declaration of Helsinki (2013 revision) and received approval from the Ethics Committee of Babol University of Medical Sciences (approval code: IR.MUBABOL.HRI.REC. 1405.177). Written informed consent was obtained from the patient for publication of this case report and any accompanying images. All procedures followed institutional guidelines, and no patient-identifying information was disclosed.

Conflicts of Interest

The authors declare no conflicts of interest.

References

1. Goetzl L. Maternal fever in labor: etiologies, consequences, and clinical management. Am J Obstet Gynecol 2023; 228(5): S1274-S82.

2. Barrios-López M, Sánchez-Bernal S, Julián Gómez E, Galante MJ, Herrán de la Gala D, González-Sánchez FJ, et al. Postpartum obstetric complications: a guide for radiologists. Abdom Radiol. 2025; 50(1):513-27.

3. Anbazhagan A, Harper A. Postpartum pyrexia. Obstet Gynaecol Reprod Med. 2015; 25(9):249-54.

[Downloaded from caspjrm.ir on 2026-11-25]

[DOI: 10.22088/caspjrm.12.1.43]

4. Silver RM, Barbour KD. Placenta accreta spectrum: accreta, increta, and percreta. Obstet Gynecol Clin North Am 2015; 42(2):381-402.

5. Zhong L, Chen D, Zhong M, He Y, Su C. Management of patients with placenta accreta in association with fever following vaginal delivery. Medicine (Baltimore). 2017; 96(10): e6279.

6. Mehrabadi A, Hutcheon JA, Liu S, Bartholomew S, Kramer MS, Liston RM, et al. Contribution of placenta accreta to the incidence of postpartum hemorrhage and severe postpartum hemorrhage. Obstet Gynecol. 2015;125(4):814-21.

7. Jauniaux E, Aplin JD, Fox KA, Afshar Y, Hussein AM, Jones CJP, et al. Placenta accreta spectrum. Nat Rev Dis Primers. 2025; 11(1):40.

8. Cahill AG, Beigi R, Heine RP, Silver RM, Wax JR. Placenta accreta spectrum. Am J Obstet Gynecol. 2018;219(6): B2-B16.

9. Kunarathnam V, Sargios M, Asad M, DeGuzman G, Udom-Rice I. Placenta Accreta Spectrum in a Patient Without Prior Cesarean Delivery: A Case of Posterior Placenta Previa. Cureus. 2026 Mar;18(3): e104559. PubMed PMID: 41930067. Pubmed Central PMCID: PMC13040601. EPUB 2026/04/03. eng.

10. Silver RM, Branch DW. Placenta accreta spectrum. N Engl J Med. 2018; 378(16):1529-36.

11. Einerson BD, Gilner JB, Zuckerwise LC. Placenta accreta spectrum. Obstet Gynec. 2023; 142(1):31.

12. Hecht JL, Baergen R, Ernst LM, Katzman PJ, Jacques SM, Jauniaux E, et al. Classification and reporting guidelines for the pathology diagnosis of placenta accreta spectrum (PAS) disorders: recommendations from an expert panel. Modern pathology: an official journal of the United States and Canadian Academy of Pathology, Inc. 2020 Dec; 33(12):2382-96. PubMed PMID: 32415266. Epub 2020/05/18. eng.

13. Jauniaux E, Jurkovic D, Hussein AM, Burton GJ. New insights into the etiopathology of placenta accreta spectrum. Am J Obstet Gynecol. 2022; 227(3):384-91.

14. Donovan BM, Shainker SA. Placenta accreta spectrum. Neoreviews. 2021; 22(11): e722-e33.

[Downloaded from caspjrm.ir on 2026-11-25]

[DOI: 10.22088/caspjrm.12.1.43]