10.22088/caspjrm.12.1.24

Caspian J Reprod Med, 2026, 12 (1): 24-33

Caspian Journal of Reproductive Medicine

Journal homepage: www.caspjrm.ir

Original

Effect of InterGuard on postoperative adhesion formation following laparoscopic surgery for advanced endometriosis: A double-blind randomized controlled trial

Mina Ataei [1,4], Khadija Shadjo [2,*], Shiva Mahmoudzadeh [3], Zahra Sehat [4]

[1] Department of Obstetrics and Gynecology, Social Determinants of Health, Research Center, School of Medical Sciences, Alborz University of Medical Sciences, Karaj, Iran

[2] Reproductive Biotechnology Research Centre, Avicenna Research Institute (ARI), Academic Centre for Education, Culture and Research (ACECR), Tehran, Iran

[3] Alborz University of Medical Sciences, Karaj, Iran

[4] Avicenna Infertility Clinic, Avicenna Research Institute (ARI), Academic Centre for Education, Culture and Research (ACECR), Tehran, Iran

Received: 15 May 2026 Accepted: 25 Jun 2026

Abstract

Background: Postoperative adhesions are a common complication following laparoscopic surgery for advanced endometriosis and may increase surgical complexity and impair reproductive function. Evidence regarding the effectiveness of adhesion prevention barriers in laparoscopic endometriosis surgery remains limited. This randomized controlled trial evaluated the effectiveness of InterGuard, an oxidized regenerated cellulose adhesion barrier, in reducing postoperative adhesion formation.

Methods: In this double-blind randomized controlled trial, 50 women undergoing laparoscopic surgery for stage III-IV endometriosis were randomly assigned to receive either InterGuard (n = 25) or saline irrigation (n = 25) following adhesiolysis. The primary outcome was the total postoperative adhesion score assessed three months after surgery using a standardized transvaginal ultrasonographic scoring system based on adhesion extent and severity. Analysis of covariance (ANCOVA) was performed to examine the influence of prespecified baseline variables on postoperative adhesion scores.

Results: All 50 randomized participants completed the study. Baseline demographic and clinical characteristics were comparable between groups. At three months, the mean postoperative adhesion score was significantly lower in the InterGuard group than in the control group (2.37 ± 0.29 vs. 6.59 ± 1.58; $P < 0.001$). After adjustment for baseline characteristics, previous abdominal surgery was the only variable significantly associated with postoperative adhesion score (partial $\eta^2 = 0.164$, $P = 0.012$).

Conclusion: InterGuard was associated with significantly lower postoperative ultrasonographic adhesion scores following laparoscopic surgery for advanced endometriosis. Given the small sample size, the use of ultrasonography rather than second-look laparoscopy, and the lack of long-term clinical outcomes, larger multicenter randomized trials are needed to confirm these findings and establish their clinical relevance.

Keywords: Endometriosis; Laparoscopy; Postoperative adhesions; Oxidized regenerated cellulose; InterGuard; Randomized controlled trial

***Correspondence author:** Dr. Khadija Shadjo, **ORCHID ID:** 0000-0001-5789-7347, Email: drshadjoo@gmail.com

This work is licensed under a Creative Commons Attribution-NonCommercial 4.0International License.
Copyright © 2020 Iranian Caspian Journal of Reproductive Medicine, and Babol University of Medical Sciences.

[Downloaded from caspjrm.ir on 2026-11-25]

[DOI: 10.22088/caspjrm.12.1.24]

Introduction

Endometriosis is a chronic inflammatory gynecological disorder characterized by the presence of endometrial-like tissue outside the uterine cavity (1). It affects approximately 6-10% of women of reproductive age and is strongly associated with infertility and chronic pelvic pain (1, 2). Women with endometriosis commonly present with infertility, pelvic pain, and ovarian endometriomas (3). Ovarian endometriomas are cystic lesions formed by ectopic endometrial tissue within the ovary and occur in approximately 17-44% of affected women (4). Although laparoscopic surgery is considered the standard treatment for advanced disease, recurrence remains common, with rates reported to reach 10% per year (5). Recurrence may result from residual lesions left after surgery or the progression of microscopic implants that are not recognized intraoperatively (6).

Despite advances in minimally invasive surgery, postoperative adhesion formation remains a major challenge following laparoscopic treatment of endometriosis. Surgical trauma to the peritoneal surface initiates an inflammatory cascade involving cytokines, growth factors, and angiogenic mediators released by activated macrophages, neutrophils, and other inflammatory cells. Reduced peritoneal fibrinolytic activity together with fibrin-rich exudate promotes the formation of a fibrin matrix that serves as a scaffold for fibroblasts, mesothelial cells, and endothelial cells, ultimately resulting in permanent fibrous adhesions (7). These adhesions may distort pelvic anatomy, impair tubo-ovarian function, contribute to chronic pelvic pain, complicate repeat surgery, and adversely affect reproductive outcomes.

Several strategies have been developed to reduce postoperative adhesion formation, including the use of physical barrier agents. Oxidized regenerated cellulose (ORC) is an absorbable biomaterial that has been widely used as a topical hemostatic agent because it promotes platelet aggregation, clot formation, and mechanical hemostasis. In addition, its acidic pH (2-4) enhances hemostasis through vasoconstriction and protein denaturation, resulting in the formation of a gel-like clot (8). ORC is generally well tolerated and is absorbed within several weeks after implantation, although foreign-body and granulomatous reactions have occasionally been reported (9).

InterGuard is an absorbable anti-adhesion barrier composed of oxidized regenerated cellulose and approved by both the Iranian Ministry of Health and the U.S. Food and Drug Administration for surgical use (10). Applied as a dry sheet over traumatized peritoneal surfaces, it acts as a temporary physical barrier during the critical early phase of peritoneal healing and has demonstrated favorable effects in reducing postoperative adhesions across various surgical procedures (10). However, most available evidence has been generated in heterogeneous gynecological populations or open surgical settings, whereas evidence regarding its effectiveness in laparoscopic surgery for advanced endometriosis remains limited and inconsistent. Given the continued clinical burden of postoperative adhesions and the scarcity of randomized evidence in women with stage III-IV endometriosis, this study aimed to evaluate the effectiveness of InterGuard in reducing postoperative adhesion formation following laparoscopic surgery for advanced endometriosis.

Materials and Methods

Study Design and Setting

This double-blind randomized controlled trial was conducted in 2022 at Avicenna Infertility Center and Kamali Hospital, Iran. The study protocol was approved by the Institutional Ethics Committee (IR.ABZUMS.REC.1401.199) and prospectively registered in the Iranian Registry of Clinical Trials (IRCT20221121056562N1). The study was conducted in accordance with the Declaration of Helsinki.

Participants

Women aged 15-45 years with surgically confirmed stage III or IV endometriosis who were scheduled for laparoscopic surgery were screened for eligibility. Endometriosis was classified according to the revised American Fertility Society (AFS) classification system. Eligible participants included women with stage III-IV endometriosis presenting with infertility, chronic cyclic pelvic pain associated with menstruation, or sonographic evidence of suspicious pelvic endometriotic lesions. Patients were excluded if they were pregnant or breastfeeding, had contraindications to laparoscopy (including coagulopathy, liver cirrhosis, severe cardiopulmonary disease, or unclear pelvic anatomy), declined participation, or withdrew consent during follow-up.

Randomization and Allocation Concealment

After confirmation of eligibility and written informed consent, participants were randomly assigned in a 1:1 ratio to the intervention or control group using block randomization. Allocation was concealed until the time of surgery to minimize selection bias.

Participants, the sonographer responsible for postoperative outcome assessment, and the statistical analyst remained blinded to treatment allocation throughout the study. Because placement of the anti-adhesion barrier was an integral component of the surgical procedure, the operating surgeon could not be blinded during the intervention.

[Downloaded from caspjrm.ir on 2026-11-25]

[DOI: 10.22088/caspjrm.12.1.24]

Intervention

Before surgery, all participants underwent transvaginal ultrasonography using a 5-7 MHz vaginal transducer (Voluson E8, GE Healthcare Austria GmbH) to confirm the diagnosis and evaluate the location and extent of endometriotic lesions. All patients subsequently underwent laparoscopic surgery for stage III-IV endometriosis. Following complete adhesiolysis, patients allocated to the intervention group received InterGuard anti-adhesion barrier placement in the rectovaginal septum (posterior cul-de-sac between the uterus and rectum). Patients in the control group underwent the identical surgical procedure but received saline irrigation instead of the anti-adhesion barrier. To reduce measurement variability, all postoperative ultrasound examinations were performed by the same experienced sonographer using the same ultrasound equipment and a standardized examination protocol.

Outcome Measures

The primary outcome was the total postoperative adhesion score assessed three months after laparoscopic surgery. Secondary outcomes included adhesion extent score, adhesion severity score, and the influence of potential confounding variables on postoperative adhesion formation.

Because second-look laparoscopy was not clinically indicated, postoperative adhesions were evaluated using transvaginal ultrasonography as a non-invasive follow-up method.

Adhesion formation was assessed at predefined postoperative pelvic sites by a single blinded sonographer. Adhesion extent was graded using a five-point scale, where 0 indicated no adhesions, 1 indicated localized involvement involving less than 25% of the evaluated area, 2 indicated involvement of 25% to 50% of the evaluated area, 3 indicated involvement of 50% to 75% of the evaluated area, and 4 indicated extensive involvement affecting more than 75% of the evaluated area. Adhesion severity was also graded on a five-point scale ranging from 0 (no adhesion) to 4 (dense vascular adhesions). The total adhesion score was calculated by multiplying the extent score by the severity score, as previously described by Krämer et al. (41). Higher scores indicated more extensive and severe postoperative adhesions.

Previous studies have reported a sensitivity of 89%, specificity of 90%, and overall diagnostic accuracy of 96% for ultrasonography in detecting postoperative pelvic adhesions (25).

Sample size

Sample size was determined using the findings reported by Krämer et al. (41) for the primary outcome (total adhesion score). Assuming a two-sided significance level of 0.05, 80% statistical power, and an anticipated 20% attrition rate, the required sample size was calculated as 24 participants per group using the formula for comparison of two independent means.

Where $\alpha = 0.05$, $\beta = 0.20$, $Z\alpha/2 = 1.96$, and $Z\beta = 0.84$

$$n = \frac{(Z_{\alpha/2} + Z_{\beta})^2 \times 2S^2}{d^2}$$

Statistical Analysis

Statistical analyses were performed using SPSS version 25 (IBM Corp., Armonk, NY, USA). The primary analysis followed the intention-to-treat principle, and all randomized participants were analyzed in their originally assigned groups. No participant was excluded from the primary analysis because complete follow-up data were available. Continuous variables are presented as mean ± standard deviation (SD), whereas categorical variables are reported as frequency and percentage. Baseline continuous variables were compared using the independent-samples t test, and categorical variables were analyzed using the Chi-square test or Fisher's exact test when appropriate. Analysis of covariance (ANCOVA) was used to compare postoperative adhesion scores between study groups while adjusting for prespecified baseline covariates considered clinically relevant. All statistical tests were two-sided, and a P value <0.05 was considered statistically significant.

Result

A total of 59 women were assessed for eligibility, of whom 50 met the inclusion criteria and were randomly assigned in a 1:1 ratio to either the InterGuard group (n = 25) or the control group (n = 25). All randomized participants completed the 3-month follow-up and were included in the final analysis (Figure 1).

The baseline demographic and clinical characteristics of the participants are summarized in Tables 1 and 2. There were no statistically significant differences between the InterGuard and control groups with respect to age, body mass index (BMI), or history of previous abdominal surgery (Table 1).

Likewise, the prevalence of previous endometriosis surgery, cesarean section, dysmenorrhea, dyspareunia, dysuria, urinary frequency, constipation, diarrhea, dyschezia, manual assistance during defecation, and rectal bleeding was comparable between the two groups (all P > 0.05; Table 2), indicating successful baseline comparability following randomization.

[Downloaded from caspjrm.ir on 2026-11-25]

[DOI: 10.22088/caspjrm.12.1.24]

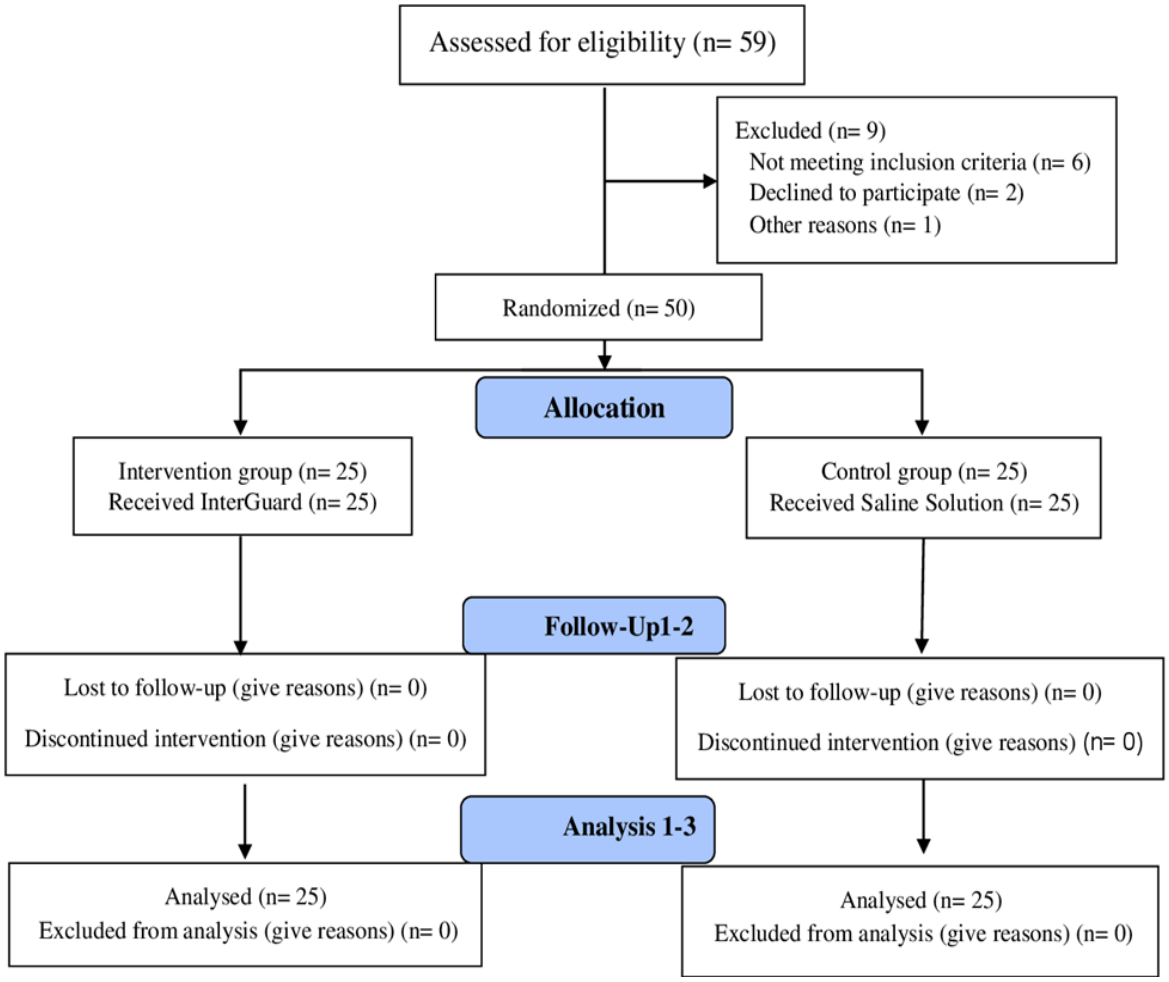

Figure 1. Consort flowchart for selecting patients in the study

Table 1. Baseline demographic characteristics of the study participants

Variable	InterGuard (n = 25)	Control (n = 25)	P
Age (years), Mean ± SD	35.4 ± 4.7	36.6 ±5.3	0.52
Body mass index (kg/m²), Mean ± SD	22.8 ± 1.6	22.5 ±2.1	0.50
Previous abdominal surgery, n (%)	4 (16.0)	3 (12.0)	0.68

Note. Continuous variables are presented as mean ± standard deviation (SD). Categorical variables are presented as number (percentage). Independent-samples t test was used for continuous variables and the chi-square test for categorical variables.

Overall, 27 participants (54.0%) were diagnosed with stage III endometriosis and 23 (46.0%) with stage IV disease. In the InterGuard group, stage III and stage IV endometriosis were observed in 15 (60.0%) and 10 (40.0%) participants, respectively, whereas in the control group, 12 (48.0%) participants had stage III and 13 (52.0%) had stage IV disease. The distribution of disease stage did not differ significantly between the two groups (Table 3).

To evaluate whether baseline characteristics influenced postoperative adhesion formation, an analysis of covariance (ANCOVA) was performed after adjustment for age, BMI, endometriosis stage, previous abdominal surgery, previous endometriosis surgery, and history of cesarean section. Among the evaluated covariates, only previous abdominal surgery was significantly associated with the postoperative adhesion score (partial $\eta^2 = .164$, $P = 0.012$), whereas age, BMI, disease stage, previous endometriosis surgery, and previous cesarean section were not

[Downloaded from caspjrm.ir on 2026-11-25]
[DOI: 10.22088/caspjrm.12.1.24]

significantly associated with the primary outcome (Table 5). The adjusted postoperative adhesion scores are presented in Figure 3.

Table2. Baseline clinical characteristics of the study participants

Variable	InterGuard n (%)	Control n (%)	P
Previous endometriosis surgery	2 (8.0)	3 (12.0)	0.63
Previous cesarean section	8 (32.0)	6 (24.0)	0.52
Dysmenorrhea	8 (32.0)	4 (16.0)	0.18
Dyspareunia	16 (64.0)	12 (48.0)	0.25
Dysuria	4 (16.0)	7 (28.0)	0.30
Urinary frequency	5 (20.0)	3 (12.0)	0.44
Constipation	4 (16.0)	2 (8.0)	0.38
Diarrhea	5 (20.0)	9 (36.0)	0.20
Dyschezia	1 (4.0)	2 (8.0)	0.55
Manual assistance during defecation	8 (32.0)	4 (16.0)	0.18
Rectal bleeding	3 (12.0)	4 (16.0)	0.68

Note. Comparisons were performed using the chi-square test or Fisher's exact test where appropriate.

Three months after laparoscopic surgery, the mean postoperative total adhesion score was significantly lower in the InterGuard group than in the control group (2.37 ± 0.29 vs. 6.59 ± 1.58, respectively; mean difference = −4.22, P < 0.001; Table 4). The distribution of postoperative adhesion scores in the two groups is illustrated in Figure 2.

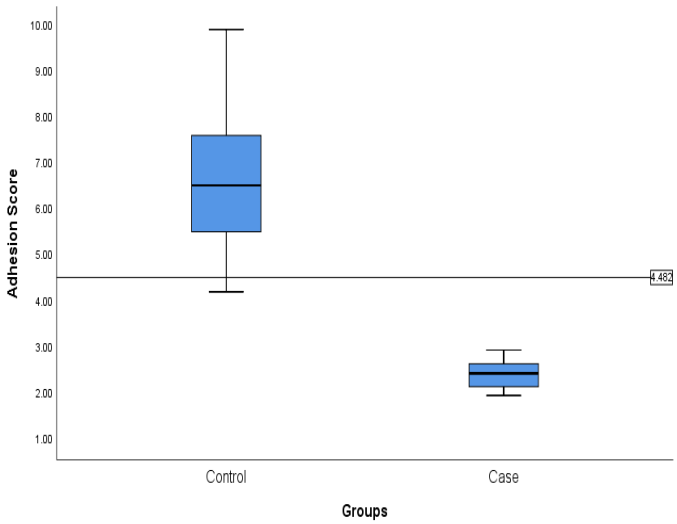

Figure 2 Boxplot of total adhesion score 3 months after laparoscopy between the two groups

Table 3. Distribution of endometriosis stage in the two study groups

Stage	InterGuard (n = 25)	Control (n = 25)	Total	P
Stage III	15 (60.0)	12 (48.0)	27(54.0)	0.395
Stage IV	10 (40.0)	13 (52.0)	23(46.0)	

Note. Comparison was performed using the chi-square test.

Table 4. Comparison of postoperative total adhesion scores between study groups

Outcome	InterGuard (n = 25) Mean ± SD	Control (n = 25) Mean ± SD	Mean difference	P
Total adhesion score	2.37 ±0.29	6.59±1.58	−4.22	<0.001

Note. Comparison was performed using the independent-samples t test.

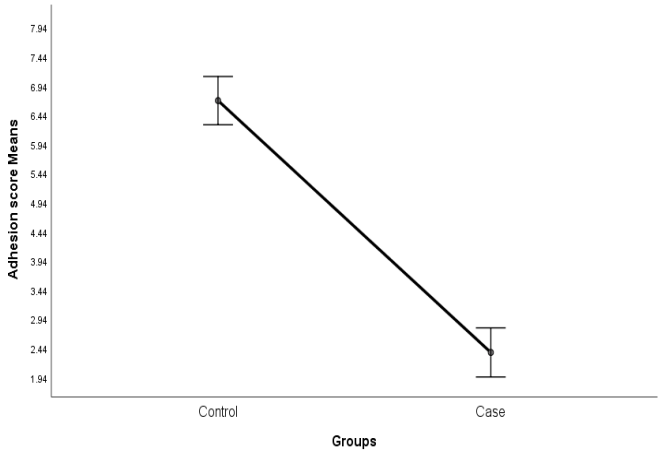

Figure 3. Error bar chart of adhesion score after removing the effect of confounding variables.

Table 5. Analysis of covariance (ANCOVA) for postoperative adhesion score

Covariate	*P*	Partial η²
Age	NS	—
Body mass index	NS	—
Endometriosis stage	NS	—
Previous abdominal surgery	0.012	0.164
Previous endometriosis surgery	NS	—
Previous cesarean section	NS	—

Note. ANCOVA was performed after adjustment for prespecified baseline covariates. NS = not statistically significant.

[Downloaded from caspjrm.ir on 2026-11-25]

[DOI: 10.22088/caspjrm.12.1.24]

Discussion

The present randomized controlled trial demonstrated that the application of InterGuard during laparoscopic surgery for stage III-IV endometriosis was associated with a significantly lower postoperative adhesion score compared with standard surgical management. After adjustment for potential baseline confounders, previous abdominal surgery was the only factor significantly associated with postoperative adhesion formation, whereas age, body mass index, disease stage, previous endometriosis surgery, and previous cesarean section showed no significant associations.

The observed reduction in postoperative adhesion formation is biologically plausible. Oxidized regenerated cellulose acts as a temporary physical barrier separating injured peritoneal surfaces during the critical early postoperative healing period, thereby reducing fibrin bridge formation and limiting the development of permanent adhesions. This mechanism has been proposed in previous experimental and clinical studies evaluating adhesion prevention materials (48).

Our findings are generally consistent with those reported by Kang et al. (39), Ten Broek et al. (45), Watanabe et al. (38), Azziz et al. (47), Gaity et al. (49), and Mais et al. (53), all of whom demonstrated a beneficial effect of oxidized regenerated cellulose-based adhesion barriers in reducing postoperative adhesion formation. However, direct comparisons should be interpreted cautiously because these studies differed with respect to surgical procedures, patient populations, study designs, adhesion assessment methods, and outcome definitions. Whereas most previous evidence has been derived from mixed gynecologic procedures or open surgery, the present study specifically evaluated women with advanced endometriosis undergoing laparoscopic surgery, a clinical setting in which adhesion formation and surgical complexity may differ substantially.

A recent systematic review by Borghese et al. (40) identified oxidized regenerated cellulose, self-crosslinked hyaluronic acid gel, and polyethylene glycol-based barriers as among the most promising adhesion prevention agents. Similarly, Salum et al. (51) reported that oxidized regenerated cellulose effectively reduced postoperative adhesion formation, while Reid et al. (52) demonstrated its greatest effectiveness during the early postoperative period when fibrin organization occurs. The findings of the present study are consistent with these reports and further support the role of oxidized regenerated cellulose as an effective adjunct for adhesion prevention following laparoscopic endometriosis surgery.

Although the postoperative adhesion score was substantially lower in the intervention group, the clinical implications of this reduction should be interpreted with caution. Pelvic adhesions are associated with infertility, chronic pelvic pain, bowel obstruction, and technical difficulty during subsequent surgery. Therefore, reducing adhesion formation may have potential clinical benefits. However, the present study did not evaluate fertility outcomes, pain recurrence, quality of life, reoperation rates, or other long-term clinical endpoints. Consequently, no direct conclusions can be drawn regarding improvements in reproductive performance or other patient-important outcomes.

No adverse events related to the intervention were observed during the study follow-up. Nevertheless, adverse events were not prospectively classified or graded using a standardized reporting system, and the relatively small sample size and limited follow-up duration restrict the ability to draw firm conclusions regarding the safety profile of InterGuard. Larger studies with systematic adverse event monitoring are required to better characterize treatment safety.

An important strength of this study is its randomized controlled design and the blinded assessment of postoperative adhesions by a single experienced sonographer, thereby reducing the potential for outcome assessment bias. In addition, baseline demographic and clinical characteristics were well balanced between the two study groups, minimizing the likelihood that measured baseline characteristics influenced the observed treatment effect.

Several limitations should be acknowledged. First, the relatively small sample size limited statistical power for detecting smaller treatment effects and precluded robust evaluation of uncommon adverse events or subgroup analyses. Second, postoperative adhesions were assessed using transvaginal ultrasonography rather than second-look laparoscopy, which remains the reference standard for adhesion assessment. Although ultrasonography has

[Downloaded from caspjrm.ir on 2026-11-25]

[DOI: 10.22088/caspjrm.12.1.24]

demonstrated acceptable diagnostic performance in previous studies (25), its accuracy depends on operator expertise and it cannot fully replace direct surgical visualization. Third, postoperative outcomes were evaluated only three months after surgery; therefore, the long-term durability of the observed reduction in adhesion formation remains uncertain. Finally, clinically important outcomes including fertility, spontaneous pregnancy, recurrence of endometriosis, chronic pelvic pain, and quality of life were not assessed.

To our knowledge, this study represents one of the few randomized clinical studies evaluating InterGuard specifically in women undergoing laparoscopic surgery for advanced endometriosis using postoperative ultrasonographic assessment. Nevertheless, because a formal systematic review was not undertaken to establish research novelty, the present findings should be interpreted as contributing additional evidence rather than establishing the first report in this field.

Conclusion

In conclusion, the use of InterGuard during laparoscopic surgery for women with stage III-IV endometriosis was associated with a significantly lower postoperative ultrasonographic adhesion score at three months compared with standard surgical management. These findings suggest that oxidized regenerated cellulose may be a useful adjunct for reducing postoperative adhesion formation in laparoscopic endometriosis surgery.

However, the findings should be interpreted in light of several limitations, including the relatively small sample size, the use of ultrasonography rather than second-look laparoscopy for adhesion assessment, and the absence of long-term clinical outcomes. Therefore, larger multicenter randomized controlled trials with standardized adhesion assessment and longer follow-up are warranted to confirm these findings and determine whether the observed reduction in adhesion scores translates into meaningful clinical benefits, including reproductive and patient-centered outcomes.

Acknowledgements

The authors would like to express their sincere appreciation to all participants who voluntarily took part in this double-blind randomized controlled trial, conducted at Avicenna Infertility Center and Kamali Hospital, Iran. The authors also gratefully acknowledge the clinical, surgical, nursing, and research staff of both centers for their valuable assistance in patient recruitment, perioperative management, data collection, and follow-up assessments. Their cooperation and support were essential to the successful completion of this study.

Conflicts of Interest

The authors declare no conflict of interest.

References

1. Acién P, Velasco I. Endometriosis: a disease that remains enigmatic. International Scholarly Research Notices. 2013;2013.
2. Obstetricians ACo, Gynecologists. Practice bulletin no. 114: management of endometriosis. Obstet Gynecol. 2010;116(1):223-36.
3. Rizk B, Fischer A, Lotfy H, Turki R, Zahed H, Malik R, et al. Recurrence of endometriosis after hysterectomy. Facts, views & vision in ObGyn. 2014;6(4):219.
4. Muzii L, Di Tucci C, Di Feliciantonio M, Galati G, Verrelli L, Di Donato V, et al., editors. Management of endometriomas. Seminars in reproductive medicine; 2017: Thieme Medical Publishers.
5. Sengoku K, Miyamoto T, Horikawa M, Katayama H, Nishiwaki K, Kato Y, et al. Clinicopathologic risk factors for recurrence of ovarian endometrioma following laparoscopic cystectomy. Acta obstetricia et gynecologica Scandinavica. 2013;92(3):278-84.
6. Ding D, Cai X, Zheng H, Guo S-W, Liu X. Scutellarin suppresses platelet aggregation and stalls lesional progression in mouse with induced endometriosis. Reproductive Sciences. 2019;26(11):1417-28.
7. Chandra A, Rho AM, Jeong K, Yu T, Jeon JH, Park SY, et al. Clinical experience of long-term use of dienogest after surgery for ovarian endometrioma. Obstetrics & gynecology science. 2018;61(1):111-7.
8. Hutchinson RW, George K, Johns D, Craven L, Zhang G, Shnoda P. Hemostatic efficacy and tissue reaction of oxidized regenerated cellulose hemostats. Cellulose. 2013;20(1):537-45.

[Downloaded from caspjrm.ir on 2026-11-25]

[DOI: 10.22088/caspjrm.12.1.24]

9. Levy M. Clinical experience with the Surgicel family of absorbable hemostats (oxidized regenerated cellulose) in neurosurgical applications. Wounds. 2013;25(6):160-7.
10. Kang HR, Choi SJ, Choi S, Lee WS. A prospective, single center, open, comparative, pilot clinical trial to evaluate the efficacy and safety of anti-adhesive agent Interguard® in patients undergoing abdominal surgery. Preprint. June 22nd, 2022.
11. Urman B. Pearls and pitfalls in surgery for endometrioma. Women's Health. 2015;11(5):677-83.
12. Thomas E, Rock J, editors. Modern approaches to endometriosis. New York: Springer Science & Business Media; 2012. p: 458-469.
13. Ashrafi M, Sadatmahalleh SJ, Akhoond MR, Talebi M. Evaluation of Risk Factors Associated with Endometriosis in Infertile Women. International journal of fertility & sterility. 2016;10(1):11-21.
14. Hemmings R, Rivard M, Olive DL, Poliquin-Fleury J, Gagné D, Hugo P, et al. Evaluation of risk factors associated with endometriosis. Fertil Steril. 2004;81(6):1513-21.
15. Johnson JE, Daley D, Tarta C, Stanciu PI. Risk of endometrial cancer in patients with polycystic ovarian syndrome: A meta‐analysis. Oncology letters. 2023;25(4):168.
16. Friedenreich CM, Derksen JWG, Speidel T, Brenner DR, Heer E, Courneya KS, et al. Case-control study of endogenous sex steroid hormones and risk of endometrial cancer. Cancer causes & control : CCC. 2020;31(2):161-71.
17. Burghaus S, Klingsiek P, Fasching PA, Engel A, Häberle L, Strissel PL, et al. Risk Factors for Endometriosis in a German Case-Control Study. Geburtshilfe und Frauenheilkunde. 2011;71(12):1073-9.
18. Hardiman P, Pillay OC, Atiomo W. Polycystic ovary syndrome and endometrial carcinoma. Lancet (London, England). 2003;361(9371):1810-2.
19. Potischman N, Hoover RN, Brinton LA, Siiteri P, Dorgan JF, Swanson CA, et al. Case-control study of endogenous steroid hormones and endometrial cancer. Journal of the National Cancer Institute. 1996;88(16):1127-35.
20. Denny E. Women's experience of endometriosis. Journal of advanced nursing. 2004;46(6):641-8.
21. Signorile PG, Baldi A. New evidence in endometriosis. The international journal of biochemistry & cell biology. 2015; 60:19-22.
22. Altman G, Wolcyzk M. Endometriosis: Overview and Recommendations for Primary Care Nurse Practitioners. The Journal for Nurse Practitioners. 2010;6(6):427-34.
23. Hirsch M, Begum MR, Paniz É, Barker C, Davis CJ, Duffy J. Diagnosis and management of endometriosis: a systematic review of international and national guidelines. BJOG: an international journal of obstetrics and gynaecology. 2018;125(5):556-64.
24. Collinet P, Fritel X, Revel-Delhom C, Ballester M, Bolze PA, Borghese B, et al. Management of endometriosis: CNGOF/HAS clinical practice guidelines - short version. Journal of gynecology obstetrics and human reproduction. 2018;47(7):265-74.
25. Guerriero S, Condous G, van den Bosch T, Valentin L, Leone FP, Van Schoubroeck D, et al. Systematic approach to sonographic evaluation of the pelvis in women with suspected endometriosis, including terms, definitions and measurements: a consensus opinion from the International Deep Endometriosis Analysis (IDEA) group. Ultrasound in obstetrics & gynecology: the official journal of the International Society of Ultrasound in Obstetrics and Gynecology. 2016;48(3):318-32.
26. Shah M, Dave B, Bhagat S, Rao H, Khadela A, Parikh N. A comprehensive review comparing conventional versus traditional remedies in the treatment of endometriosis with futuristic insights. Future Journal of Pharmaceutical Sciences. 2024;10(1):35.
27. Olive DL, Pritts EA. Treatment of endometriosis. New England Journal of Medicine. 2001;345(4):266-75.
28. Izawa M, Taniguchi F, Terakawa N, Harada T. Epigenetic aberration of gene expression in endometriosis. Front Biosci (Elite Ed). 2013;5(3):900-10.
29. Matalliotakis M, Goulielmos GN, Kalogiannidis I, Koumantakis G, Matalliotakis I, Arici A. Extra pelvic endometriosis: retrospective analysis on 200 cases in two different countries. European Journal of Obstetrics & Gynecology and Reproductive Biology. 2017; 217:34-7.

[Downloaded from caspjrm.ir on 2026-11-25]

[DOI: 10.22088/caspjrm.12.1.24]

30. Garcia L, Isaacson K. Adenomyosis: review of the literature. Journal of minimally invasive gynecology. 2011;18(4):428-37.
31. Agarwal SK, Chapron C, Giudice LC, Laufer MR, Leyland N, Missmer SA, et al. Clinical diagnosis of endometriosis: a call to action. American journal of obstetrics and gynecology. 2019;220(4):354. e1-. e12.
32. Farag S, Padilla PF, Smith KA, Sprague ML, Zimberg SE. Management, prevention, and sequelae of adhesions in women undergoing laparoscopic gynecologic surgery: a systematic review. Journal of Minimally Invasive Gynecology. 2018;25(7):1194-216.
33. Patel S, Yadav A. Prevention of adhesion in laparoscopic gynaecological surgery. International Journal of Reproduction, Contraception, Obstetrics and Gynecology. 2016;5(12):4099-106.
34. Ellis H. The causes and prevention of intestinal adhesions. British journal of Surgery. 1982;69(5):241-3.
35. Monk BJ, Berman ML, Montz F. Adhesions after extensive gynecologic surgery: clinical significance, etiology, and prevention. American journal of obstetrics and gynecology. 1994;170(5):1396-403.
36. Diamond MP. Reduction of postoperative adhesion development. Fertility and sterility. 2016;106(5):994-7. e1.
37. Torres-De La Roche L, Campo R, Devassy R, Sardo ADS, Hooker A, Koninckx P, et al. Adhesions and anti-adhesion systems highlights. Facts, Views & Vision in ObGyn. 2019;11(2):137.
38. Watanabe J, Ishida F, Ishida H, Fukunaga Y, Watanabe K, Naito M, et al. A prospective multi-center registry concerning the clinical performance of laparoscopic colorectal surgery using an absorbable adhesion barrier (INTERCEED®) made of oxidized regenerated cellulose. Surgery today. 2019;49:877-84.
39. Kang H-R, Choi SJ, Choi S, Lee W-S. A prospective, single center, open, comparative, pilot clinical trial to evaluate the efficacy and safety of anti-adhesive agent Interguard® in patients undergoing abdominal surgery. Research Square; 2022.
40. Borghese G, Raffone A, Raimondo D, Saccone G, Travaglino A, Degli Esposti E, et al. Adhesion barriers in laparoscopic myomectomy: Evidence from randomized clinical trials. International Journal of Gynecology & Obstetrics. 2021;152(3):308-20.
41. Krämer B, Andress J, Neis F, Hoffmann S, Brucker S, Kommoss S, et al. Adhesion prevention after endometriosis surgery - results of a randomized, controlled clinical trial with second-look laparoscopy. Langenbeck's archives of surgery. 2021;406(6):2133-43.
42. Huang C, Ding DC. Outcomes of adhesion barriers in gynecologic surgeries: A retrospective study at a medical center. Medicine (Baltimore). 2019;98(50):e18391.
43. Hsu C-W, Chang M-C, Wang J-H, Wu C-C, Chen Y-H. Placement of SurgiWrap® adhesion barrier film around the protective loop stoma after laparoscopic colorectal cancer surgery may reduce the peristomal adhesion severity and facilitate the closure. International journal of colorectal disease. 2019;34(3):513-8.
44. Shaltout MF, Elsheikhah A, Maged AM, Elsherbini MM, Zaki SS, Dahab S, et al. A randomized controlled trial of a new technique for laparoscopic management of ovarian endometriosis preventing recurrence and keeping ovarian reserve. J Ovarian Res. 2019;12(1):66.
45. Ten Broek RP, Stommel MW, Strik C, van Laarhoven CJ, Keus F, van Goor H. Benefits and harms of adhesion barriers for abdominal surgery: a systematic review and meta-analysis. The Lancet. 2014;383(9911):48-59.
46. Rock JA, Group ZES. The revised American Fertility Society classification of endometriosis: reproducibility of scoring. Fertility and sterility. 1995;63(5):1108-10.
47. Azziz R, Murphy A, Rosenberg S, Patton Jr G. Use of an oxidized, regenerated cellulose absorbable adhesion barrier at laparoscopy. The Journal of Reproductive Medicine. 1991;36(7):479-82.
48. Takagi K, Araki M, Fukuoka H, Takeshita H, Hidaka S, Nanashima A, et al. Novel powdered anti-adhesion material: preventing postoperative intra-abdominal adhesions in a rat model. International journal of medical sciences. 2013;10(4):467.

[Downloaded from caspjrm.ir on 2026-11-25]

[DOI: 10.22088/caspjrm.12.1.24]

49. Gaity A, Helena O, Akshay H, Andrew W. Barrier agents for adhesion prevention after gynaecological surgery. Cochrane Database Syst Rev. 2015;4.
50. Ahmad G, Kim K, Thompson M, Agarwal P, O'Flynn H, Hindocha A, et al. Barrier agents for adhesion prevention after gynaecological surgery. Cochrane Database of Systematic Reviews. 2020(3).
51. Salum M, Wexner S, Nogueras J, Weiss E, Koruda M, Behrens K, et al. Does sodium hyaluronate-and carboxymethylcellulose-based bioresorbable membrane (Seprafilm) decrease operative time for loop ileostomy closure? Techniques in coloproctology. 2006; 10:187-91.
52. Reid RL, Hahn PM, Spence JE, Tulandi T, Yuzpe AA, Wiseman DM. A randomized clinical trial of oxidized regenerated cellulose adhesion barrier (Interceed, TC7) alone or in combination with heparint. Fertility and sterility. 1997;67(1):23-9.
53. Mais V, Ajossa S, Piras B, Guerriero S, Marongiu D, Melis G. Prevention of de-novo adhesion formation after laparoscopic myomectomy: a randomized trial to evaluate the effectiveness of an oxidized regenerated cellulose absorbable barrier. Human reproduction. 1995;10(12):3133-5.

[Downloaded from caspjrm.ir on 2026-11-25]

[DOI: 10.22088/caspjrm.12.1.24]