

## Uterine scar silent rupture following induction of second trimester abortion: A rare case report

Swathi Aswath<sup>1\*</sup>, Ratna Blulusu<sup>1</sup>, Pooja Shivaraj<sup>1</sup><sup>1</sup> Department of OBG, East Point Institute Medical Science and Research Center, Bengaluru, Karnataka, India

Received: 11 Agus 2024 Accepted: 20 Dec 2024

### Abstract

Uterine rupture is a rare but serious complication, especially in women with prior cesarean delivery. This case describes a 28-year-old with intrauterine fetal demise and failed second-trimester abortion induction. During hysterectomy, the fetus and placenta were found extruded into the right broad ligament, mimicking a broad ligament pregnancy, with a rupture at the previous cesarean scar. The patient remained stable, with no significant hemorrhage or peritoneal irritation. This case emphasizes early recognition, timely intervention, and individualized management in high-risk patients. Vigilant monitoring and a multidisciplinary approach are crucial to optimizing maternal outcomes in such complex scenarios.

**Keywords:** Cesarean, Hemorrhage, Hysterectomy, Uterine rupture

### Introduction

Uterine rupture is a rare but severe obstetric complication that poses significant risks to both maternal and fetal health. It involves a complete disruption of the uterine wall, which can occur during or before labor, particularly in women with a history of uterine surgery, such as cesarean deliveries. The risk of uterine rupture is significantly higher in scarred uteri, with an estimated incidence of 1% to 1.3% compared to much lower rates in unscarred uteri. The potential consequences are catastrophic, including severe maternal hemorrhage, hysterectomy, and increased morbidity and mortality for both the mother and fetus (1-3).

This case report describes a rare instance of uterine scar rupture during second-trimester abortion induction for intrauterine fetal demise. The patient underwent both medical and mechanical methods for abortion induction but did not respond adequately, requiring surgical intervention via hysterectomy. During the procedure, the fetus and placenta were unexpectedly located between the layers of the right broad ligament,

mimicking a broad ligament pregnancy. Additionally, a bucket-handle tear was identified at the site of the previous cesarean scar, underscoring the complexities in managing such cases.

### Case Presentation

A 28-year-old woman, G3P2L2, presented with a five-month pregnancy and a history of vaginal leakage for three days. Ultrasound confirmed intrauterine fetal demise. Her obstetric history included one vaginal delivery five years ago and a lower-segment transverse cesarean section two years prior. On examination, her vital signs were stable (pulse 80/min; BP 110/70 mmHg), and abdominal palpation revealed a uterus consistent with 24 weeks of gestation. Fetal heart activity was absent.

A follow-up ultrasound confirmed fetal demise with breech presentation at approximately 20 weeks and 5 days gestation, an anteriorly positioned placenta, and absent amniotic fluid. Laboratory investigations, including a complete blood count and renal function tests, were within normal limits. After detailed counseling on the risks and benefits of medical versus surgical abortion methods, the patient opted for

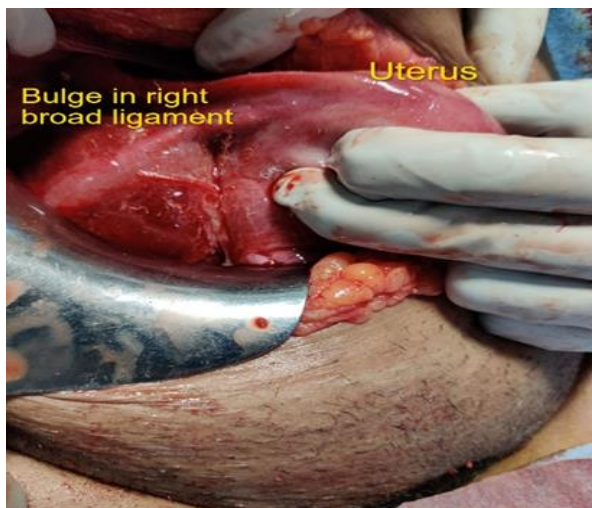
\*Correspondence author: Dr. Swathi Aswath, Villa 72, Allure one Villas, Kithaganur Main road, KR Puram, Bengaluru, Karnataka- 560049

Email: [swathidlc@gmail.com](mailto:swathidlc@gmail.com) Tel: 0091984429737

medical management using mifepristone and misoprostol.

On Day 1, the patient received 200 mg of mifepristone orally. On Day 2, a Foley catheter bulb inflated with 40 ml of distilled water was inserted for mechanical induction (4). By Day 3 (48 hours post-mifepristone), her vitals remained stable, but uterine contractions were absent. Consequently, misoprostol (200 mcg sublingually) was administered, followed by an additional oral dose four hours later. Although contractions initially developed, they subsided within four hours, leading to the initiation of oxytocin at a rate of 8 drops/min to enhance uterine activity.

After four days of unsuccessful induction attempts and no improvement in the Bishop score, a decision was made to proceed with hysterectomy. Intraoperatively, the uterus was found to be approximately 12 weeks in size with an unexpected bulge in the right broad ligament. Initially suspected as a hematoma, the structure was later identified as mimicking a broad ligament pregnancy due to an empty uterine cavity (Figure 1).

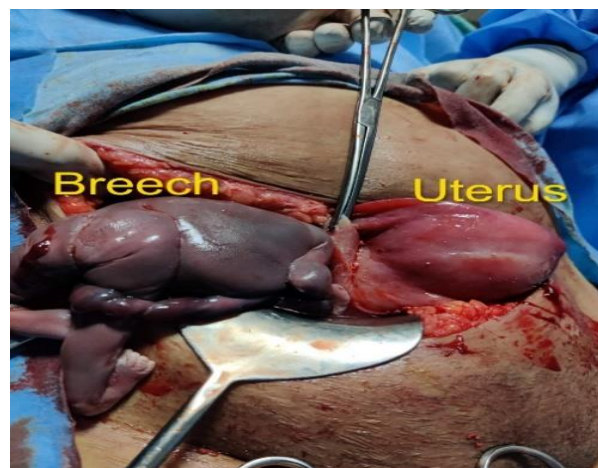


**Figure 1.** Empty bulky uterus with bulge in right broad ligament

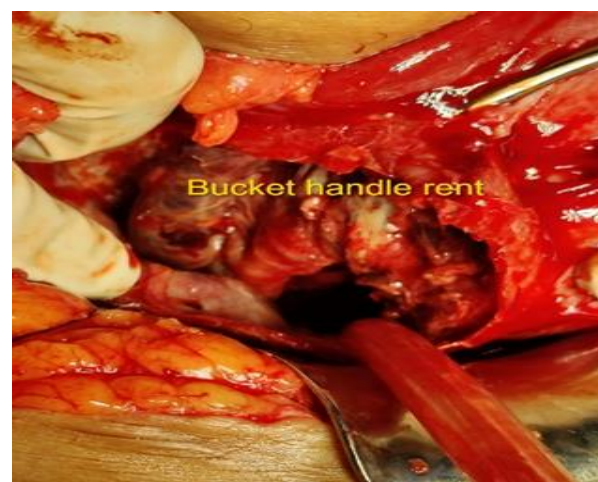
Upon incision into the right broad ligament, a dead macerated fetus weighing 380 grams was delivered in breech presentation (Figure 2), followed by removal of the placenta without active bleeding. Further exploration revealed a bucket-handle rupture at the site of the previous cesarean scar. The rupture was repaired with sutures, and a bilateral tubectomy was performed

(Figure 3). No complications such as hemoperitoneum or pelvic organ injury were observed.

The patient had an uneventful recovery postoperatively, and follow-up visits confirmed stable health.



**Figure 2.** Fetus extracted by Breech from layers of broad ligament



**Figure 3.** Bucket handle rent in uterus

## Discussion

Over the past few decades, cesarean delivery rates have risen globally, resulting in more women carrying uterine scars into subsequent pregnancies. This history significantly increases the risk of complications, including uterine scar dehiscence and rupture (5). While strategies to reduce the risk of uterine rupture in high-risk patients are critical, the trend toward medical management has led to a decline in surgical interventions (6).

In this case, the patient remained hemodynamically stable throughout the induction process, with no evidence of fresh vaginal bleeding. The uterine rupture

occurred within the fibrotic tissue of the previous cesarean scar, which limited the extent of intraperitoneal complications. Consequently, the patient did not exhibit signs of shock or intraperitoneal bleeding. This was attributed to the unique extrusion of the fetus and placenta into the layers of the right broad ligament, preventing direct peritoneal irritation by amniotic fluid or fetal tissue.

Pre-induction ultrasound identified a breech presentation with an anteriorly positioned placenta. Following the rupture, the breech passed through the uterine rent, with the fetal trunk and head subsequently displaced into the upper broad ligament. Notably, there was no significant hemorrhage after the fetus and placenta were removed. This unusual presentation underscores the importance of vigilant monitoring and tailored management in patients with a history of uterine scarring.

### Conclusion

This case highlights a rare and unusual presentation of uterine scar rupture during second-trimester abortion induction, where the fetus and placenta were extruded into the broad ligament, mimicking a broad ligament pregnancy. Despite the rupture, the absence of significant hemorrhage or peritoneal irritation due to the contained extrusion underscores the variability in clinical presentations of uterine rupture.

The findings emphasize the importance of individualized management in patients with a history of cesarean delivery, particularly during induction of labor or abortion in the second trimester. Early recognition of uterine rupture, timely surgical intervention, and meticulous intraoperative exploration are crucial to optimizing maternal outcomes. This case also underlines the need for a multidisciplinary approach to ensure safe and effective care for high-risk obstetric patients.

### Acknowledgements

We appreciate the contributions of the participants involved in this study, whose cooperation made this work possible.

### Conflicts of Interest

We have no commercial or financial gains for this study.

### References

1. Henkel A, Miller HE, Zhang J, Lyell DJ, Shaw KA. Prior Cesarean Birth and Risk of Uterine Rupture in Second-Trimester Medication Abortions Using Mifepristone and Misoprostol: A Systematic Review and Meta-analysis. *Am J Obstet Gynecol* 2023; 142(6): 1357-64.
2. Zhan W, Zhu J, Hua X, Ye J, Chen Q, Zhang J. Epidemiology of uterine rupture among pregnant women in China and development of a risk prediction model: analysis of data from a multicentre, cross-sectional study. *BMJ open* 29; 11(11): e054540.
3. Grossetti E, Vardon D, Creveuil C, Herlicoviez M, Dreyfus M. Rupture of the scarred uterus. *Acta Obstet Gynecol Scand* 2007; 86(5): 572-8.
4. Chandrasekaran S, Paul M, Ruggiero S, Monschauer E, Blanchard K, Robinson Y. Foley catheter and misoprostol for cervical preparation for second-trimester surgical abortion. *Contraception* 2021; 104(4): 437-41.
5. Golshahi F, Yarandi F, Ramhormozian S, Shirali E. Lessons Learnt from Cases of Misoprostol-Based Pregnancy Termination Followed by Uterine Rupture: Report of 3 Cases. *J obstet gynecol cancer Res* 2021; 7(2): 121-5.
6. Stephenson ML, Wing DA. Misoprostol for induction of labor. *Seminars in perinatology*. 2015; 39(6): 459-62.