

## Endometrial pathologies in abnormal uterine bleeding: prevalence, patterns, and perspectives: A cross sectional study

Mahesh Asalkar<sup>1,\*</sup>, Ilaaf Rumani<sup>1</sup>, Mangal Supe<sup>1</sup>, Smita Thakkarwad<sup>1</sup>, Sinchana R<sup>1</sup>

<sup>1</sup> Department of Obstetrics and Gynaecology, PGI-YCMH Pimpri Pune 411018(MS) India, Department of Obstetrics and Gynaecology, PGI-YCMH Pimpri Pune 411018(MS), India

Received: 26 Feb 2024 Accepted: 2 May 2024

### Abstract

**Background:** Abnormal uterine bleeding (AUB) is a common gynecological challenge, stemming from various endometrial pathologies. This study aims to assess their prevalence, age distribution, symptomatology correlation, and compare sampling techniques.

**Methods:** This prospective cross-sectional study was conducted at a single teaching institute, involving 150 female participants aged between 18 and 70 years who presented with AUB. Endometrial samples were collected using one of three methods: OPD Pipelle brush, surgical dilatation and curettage (D&C), or hysteroscopy.

**Results:** The study found 41-50-year-olds most affected by AUB (40%), with 64% having given birth three or more times. Proliferative and secretory changes were common (35.3% and 16% respectively). Endometrial hyperplasia without atypia occurred in 12% and with atypia in 4.7%. Endometrial carcinoma was in 3.3% and polyps in 5.3% of cases. Heavy menstrual bleeding with normal duration affected 64%. Technical challenges included sampling failure in 2 pipelle biopsies and 7 D&C cases. Inadequate samples were obtained in 2 pipelle biopsy and 5 D&C cases. Uterine perforation occurred once, managed conservatively.

**Conclusion:** Our study underscores the burden of endometrial pathologies in AUB patients with predominant proliferative and secretory changes. Sampling challenges, particularly with pipelle biopsy and D&C, emphasize the need for refining methods and exploring alternatives like transvaginal sonography and hysteroscopy to enhance diagnostic accuracy and patient outcomes in AUB management.

**Keywords:** Abnormal Uterine Bleeding (AUB), Cross-sectional Study, Endometrial Pathology, Endometrial Sampling Techniques, Evaluation

### Introduction

Abnormal uterine bleeding (AUB) encompasses a spectrum of menstrual irregularities that affect many women, characterized by changes in the amount, pattern, and timing of menstrual bleeding (1). This condition often prompts women to seek medical attention from gynecologists due to its disruptive nature and potential underlying causes related to the endometrium (2). AUB can manifest in various forms such as heavy menstrual bleeding with normal duration (HMB), prolonged heavy bleeding, bleeding between

periods (intermenstrual bleeding), or bleeding after menopause (3).

These symptoms can have a profound impact on a woman's quality of life, emphasizing the importance of early detection and appropriate management to prevent complications and improve overall well-being (4).

Transvaginal ultrasonography (TVS) is a valuable tool in the evaluation of AUB, providing detailed information about the structure and health of the uterus and endometrium (5). This imaging technique aids in identifying any structural abnormalities or pathologies that may be contributing to abnormal bleeding (6).

\*Correspondence author: Mahmood Dr. MR Asalkar, Professor & Head, Department of Obstetrics and Gynaecology, PGI-YCMH Pimpri Pune 411018(MS)India, Department of Obstetrics and Gynaecology, PGI-YCMH Pimpri Pune 411018(MS) India, Tel: +91 9326972948  
Email: [mahesh@asalkarclinic.com](mailto:mahesh@asalkarclinic.com)

Additionally, endometrial sampling techniques like pipelle biopsy or dilatation and curettage (D&C) are essential for obtaining tissue samples for further examination to determine the underlying cause of AUB (7).

Hysteroscopy is another important diagnostic and therapeutic procedure used in the management of AUB. By allowing direct visualization of the uterine cavity, hysteroscopy enables healthcare providers to identify and treat any abnormalities or lesions within the uterus. This procedure can be performed in different settings based on individual patient needs and the complexity of the case (8).

In summary, AUB is a common gynecological issue that can significantly impact a woman's physical and emotional well-being (9). The combination of transvaginal ultrasonography, endometrial sampling, and hysteroscopy plays a crucial role in the comprehensive evaluation and management of AUB by identifying and addressing the underlying endometrial conditions effectively. Early intervention and personalized treatment plans can lead to improved outcomes and quality of life for women experiencing abnormal uterine bleeding (10).

This study aims to analyze the prevalence of various endometrial pathologies in patients with abnormal uterine bleeding, focusing on age-related distribution. Additionally, it seeks to explore age-specific clinical presentations and compare techniques for endometrial sample collection. By addressing these objectives, the study aims to enhance the understanding and management of abnormal uterine bleeding associated with diverse endometrial pathologies across different age groups.

### Materials & Methods

This study received approval from the PGI-YCMH Ethical Committee, situated in Pimpri, Pune, India [Approval No. YCMH/PG/ETHICS/11/2019 dated 01/11/2019], and was conducted at PCMC's PGI and Y C M Hospital in Pune from January 1, 2020, to May 31, 2021. We enrolled 150 female participants aged 18 to 70 years who presented with Abnormal Uterine Bleeding. Informed consent was obtained from all participants before enrollment.

The primary objective was to analyze the prevalence of various endometrial pathologies among patients with abnormal uterine bleeding. Secondary objectives included studying the age-wise distribution of these pathologies, assessing age-wise clinical presentations (symptomatology) in AUB patients, and comparing the feasibility of different endometrial sampling techniques. Inclusion criteria encompassed patients aged 18 to 70 presenting symptoms of AUB who underwent endometrial biopsy. Unmarried patients with suspected sinister pathology (non-benign) were also considered for endometrial sampling.

Exclusion criteria involved unmarried patients undergoing primary conservative management for suspected benign pathology, as no endometrial sampling was performed despite AUB symptoms, and patients who declined to consent for participation. Endometrial biopsy samples were collected using the OPD Pipelle brush, Surgical Dilatation and Curettage method, or hysteroscopy with endometrial biopsy. Histopathological diagnoses were examined for all samples, with data collected in a standardized format specified in the data collection tool.

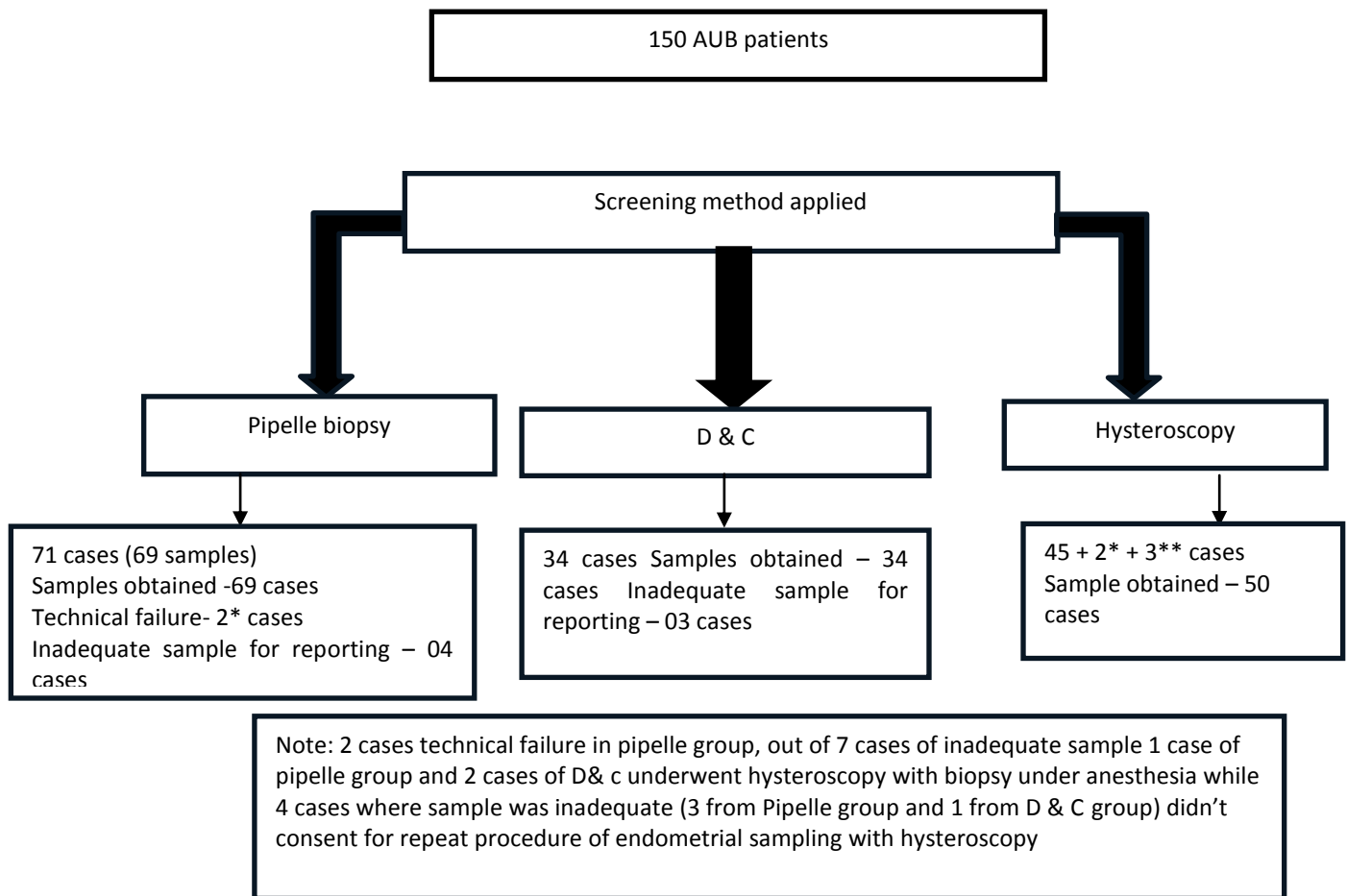
Unmarried patients with suspected sinister pathology (non-benign) were also considered for endometrial sampling. Exclusion criteria involved unmarried patients undergoing primary conservative management for suspected benign pathology, as no endometrial sampling was performed despite AUB symptoms, and patients who declined to consent for participation.

Endometrial biopsy samples were collected using the OPD Pipelle brush, Surgical Dilatation and Curettage method, or hysteroscopy with endometrial biopsy. Histopathological diagnoses were examined for all samples, with data collected in a standardized format specified in the data collection tool.

### Results

This study included 150 female patients aged 18 to 70 with Abnormal Uterine Bleeding (AUB), with a majority having given birth three or more times (64%) and belonging to the lower socio-economic class (54.6%) (Fig 1).

Table 1 and Table 2 detail the spectrum of endometrial pathologies by age group.



**Figure 1.** Flow chart of the study

In the 21-30 age group, 4.5% underwent sampling, mainly showing benign changes like proliferative and secretory endometrium, chronic endometritis, and polyps. The 31-40 age group had 35.3% sampled, with similar benign changes along with endometrial hyperplasia and polyps. The 41-50 age group had the most cases (40%), showing various pathologies including hyperplasia, carcinoma, and chronic endometritis. The 51-60 age group accounted for 14% of cases, with diverse histopathological findings. Only 5.2% of the 61-70 age group underwent sampling, revealing carcinoma, atrophy, and polyps.

Table 3 indicates that heavy menstrual bleeding with normal duration (HMB) was the most common clinical presentation (64%), followed by heavy and prolonged bleeding (15.3%), post-menopausal bleeding (15.3%), and intermenstrual bleeding (IMB) (5.4%).

Table 4 illustrates the sampling techniques employed. Out of 150 patients, 71 underwent pipelle biopsy, with a success rate of 97.2% and 2 cases of technical failure. Dilatation and curettage were performed on 34 patients, and hysteroscopy with biopsy on 47. Additionally, three cases underwent repeat hysteroscopy due to inadequate samples. Inadequate sampling was noted in 4 pipelle biopsies

and 3 dilatation and curettage cases. One uterine perforation occurred during dilatation and curettage. Pipelle biopsy proved more feasible for outpatient procedures, while dilatation and curettage and hysteroscopy with biopsy were less feasible in this setting.

**Table 1.** Sociodemographic parameters of patients with AUB

Age group	Frequency	Percentage
21-30 years	07	04.5
31-40 years	53	35.3
41-50 years	60	40.0
51-60 years	22	15.0
61-70 years	08	05.2
<b>Parity</b>		
Zero	4	02.7
1	5	03.3
2	45	30.0
>3	96	64.0
<b>Socioeconomic status</b>		
Upper	25	16.7
Middle	43	28.7
Lower	82	54.6

**Table 2.** Histopathological features and age group

Histological pattern of endometrium	Age (years)					Total, n (%)
	21-30	31-40	41-50	51-60	61-70	
Proliferative endometrium	2	23	22	6	0	53(35.4)
Disordered proliferative endometrium	0	3	4	1	0	8(5.3)
Secretory endometrium	1	11	12	0	0	24(16.0)
Endometrial hyperplasia without atypia	0	4	7	6	1	18(12.0)
Endometrial hyperplasia with atypia	0	2	3	2	0	7(4.7)
Atrophic endometrium	0	0	0	2 (+1*)	2 (+1*)	4 (+2) (4.0)
Endometrial carcinoma	0	0	1	1	3	5(3.3)
Chronic endometritis	1	3	5 (+1*)	2	0	11 (+1) (8.0)
Pill endometrium	2	2	1	0	0	5(3.3)
Endometrial polyp	1	3	2	1	1	8(5.3)
Inadequate sample	0	2	3 (-1)	1(-1)	1(-1)	7(-3) (4.7)
Percentage (%)	4.5	35.3	40.0	15	5.3	

Figures in bracket indicate repeat procedure due to inadequate sample (Refer to footnote in methodology flow chart)

**Table 3.** Age group and clinical presentation

Clinical presentation	Age (in years)					Total	Percentage (%)
	21-30	31-40	41-50	51-60	61-70		
Heavy and prolonged menstrual bleeding	0	13	8	2	0	23	15.3
Heavy menstrual bleeding with normal duration	6	36	45	9	0	96	64.0
Intermenstrual bleeding	1	4	3	0	0	8	05.4
Postmenopausal bleeding	0	0	4	11	8	23	15.3
Total	7	53	60	22	08	150	
Percentage (%)	4.5	35.4	40	14.7	5.4		100

**Table 4.** Comparison of different methods used for endometrial biopsy

	Pipelle Biopsy	D & c	Hscopy with biopsy	Total
Total cases	69#	34	45+2*+3**	150 (153**)
Technical failure	02	---	---	02 *
Inadequate sample	04	03	---	07
Repeat Sample by hysteroscopy	01	02	---	03**
Feasibility of procedure	More	Less	Less	--
Rare complication Perforation	0	1	0	1

## Discussion

AUB is a common gynecological concern affecting women of diverse age groups, with a higher prevalence noted in older individuals. Our study identified the 41-50 age group as the most frequently affected by AUB, followed by the 31-40 age bracket, comprising 75.3% of cases. This finding is consistent with previous research conducted by Doraiswami et al., (1) Muzaffar et al., (11) and Yusuf et al., (12).

In our study, 96 out of 150 patients with AUB had given birth three or more times, while nulliparous women accounted for only 2.7%. This observation is in line with previous studies, which have consistently reported a lower incidence of AUB in nulliparous women compared to those who have given birth multiple times. Furthermore, we observed that patients seeking care at public sector health facilities predominantly come from lower socio-economic backgrounds, corroborating findings from prior research (1).

The results of our study highlight the prevalence of various endometrial pathologies among patients with AUB. Functional endometrium with proliferative and secretory changes were noted in 35.4% and 16% of cases, respectively. Additionally, endometrial hyperplasia without atypia was observed in 12% of cases, while endometrial hyperplasia with atypia was found in 4.66% of cases. Endometrial hyperplasia is a significant concern as it serves as a precursor lesion for endometrial cancer. Our findings underscore the importance of promptly addressing endometrial hyperplasia and providing counseling to patients regarding the nature of the pathology detected and the appropriate treatment to be initiated.

Furthermore, our study identified endometrial carcinoma in 3.3% of cases. The incidence of detecting carcinoma in endometrial samples varies depending on the population screened. AUB patients attending general gynecology outpatient departments may have a lower incidence of carcinoma detection, while patients with high-risk factors such as obesity, nulliparity, family history, or those from oncological hospitals may report a higher detection rate for malignancy. Overall, these results emphasize the importance of thorough evaluation and management of endometrial pathologies in patients presenting with AUB, especially considering the potential progression to malignancy in cases of hyperplasia and carcinoma. Early detection and intervention are crucial for optimizing patient outcomes and reducing the risk of cancer development. Atrophic endometrium was observed in 6 cases (4%), a rate consistent with findings reported by Brahmaiah et al. and other authors (13), ranging from 2-7.38%. The bleeding in these patients may be attributed to the rupture of dilated blood capillaries beneath the surface of the atrophic endometrium.

Furthermore, our study identified endometrial carcinoma in 3.3% of cases. The incidence of detecting

carcinoma in endometrial samples varies depending on the population screened. AUB patients attending general gynecology outpatient departments may have a lower incidence of carcinoma detection, while patients with high-risk factors such as obesity, nulliparity, family history, or those from oncological hospitals may report a higher detection rate for malignancy. Overall, these results emphasize the importance of thorough evaluation and management of endometrial pathologies in patients presenting with AUB, especially considering the potential progression to malignancy in cases of hyperplasia and carcinoma. Early detection and intervention are crucial for optimizing patient outcomes and reducing the risk of cancer development. Atrophic endometrium was observed in 6 cases (4%), a rate consistent with findings reported by Brahmaiah et al. and other authors (13) ranging from 2-7.38%. The bleeding in these patients may be attributed to the rupture of dilated blood capillaries beneath the surface of the atrophic endometrium.

Postmenopausal bleeding was noted in 15.3% in our study, with Kafle et al. (15) reporting a 19.27% incidence of postmenopausal bleeding and Vijayraghavan et al. (14) reporting a 12.5% incidence. Proper evaluation of postmenopausal bleeding is essential to rule out serious pathology, as 90% of women with endometrial cancer present with postmenopausal bleeding, although the majority have a benign underlying cause for their symptoms.

Our study provides insights into age-related endometrial conditions in AUB patients. Most affected were 41-50-year-olds, with common proliferative and secretory alterations. Additionally, 5.3% had endometrial polyps, 12% hyperplasia without atypia, and 4.66% with atypia. Endometrial cancer was detected in 3.3%. Challenges included inadequate samples (4.6%), technical failure (1.3%), and one uterine perforation (0.33%). These findings stress careful sampling and improved methodologies for AUB evaluation.

The study demonstrated strengths in systematic data collection; however, its scope was confined to clinical and histopathological diagnoses, lacking insights into treatment outcomes and post-surgery comparisons. Conducted within a tertiary teaching hospital, the findings hold potential for generalization to akin populations experiencing AUB. Nevertheless, it is pertinent to acknowledge that pathology incidences may vary across distinct age groups or among individuals with high-risk factors.

## Conclusion

Our study offers insights into demographic characteristics, clinical presentations, and diagnostic approaches in AUB patients. Most were multiparous from lower socio-economic backgrounds. Endometrial pathologies varied by age, with the 41-50 group having the highest prevalence. Heavy menstrual bleeding was

the predominant clinical presentation. Pipelle biopsy proved effective for outpatient use, while other techniques faced challenges. These findings inform AUB management and underscore the importance of tailored diagnostic approaches.

## Acknowledgements

Our sincere gratitude goes to all supervisors, data collectors, ANMs, study participants with their family members for their cooperation and support.

## Conflicts of Interest

None to declare.

## References

- Jain V, Munro MG, Critchley HO. Contemporary evaluation of women and girls with abnormal uterine bleeding: FIGO systems 1 and 2. *Int J Gynaecol Obstet* 2023; 162: 29-42.
- Tsolova AO, Aguilar RM, Maybin JA, Critchley HO. Pre-clinical models to study abnormal uterine bleeding (AUB). *EBioMedicine* 2022; 84.
- Jain V, Chodankar RR, Maybin JA, Critchley HO. Uterine bleeding: how understanding endometrial physiology underpins menstrual health. *Nat Rev Endocrinol* 2022; 18(5): 290-308.
- Dudek JE, Białaszek W, Gabriel M. Quality of life, its factors, and sociodemographic characteristics of Polish women with lipedema. *BMC Womens Health* 2021; 21: 1-9.
- Jayni D. Comparison of Transvaginal Ultrasound, Saline Infusion Sonohysterography Versus Diagnostic Hysteroscopy in Evaluation of Endometrial Cavity Pathology Amongst Women With Abnormaluterine Bleeding in Nairobi. a Prospective Cohort Study: UON; 2021.
- Quesada J, Härmä K, Reid S, Rao T, Lo G, Yang N, et al. Endometriosis: A multimodal imaging review. *Eur J Radiol* 2023; 158: 110610.
- Padmavathy Soundariaeswari R. Clinicopathological study of Abnormal Uterine Bleeding in Perimenopausal Women: Madras Medical College, Chennai; 2020.
- Gkrozou F, Tsonis O, Dimitriou E, Paschopoulos M. In women with chronic or subclinical endometritis is hysteroscopy suitable for setting the diagnosis? A systematic review. *J Obstet Gynaecol Res* 2020; 46(9): 1639-50.
- Vitale SG, Watrowski R, Barra F, et al. Abnormal uterine bleeding in perimenopausal women: the role of hysteroscopy and its impact on quality of life and sexuality. *Diagnostics* 2022; 12(5): 1176.
- Long B, Clarke MA, Morillo ADM, Wentzensen N, Bakkum-Gamez JN. Ultrasound detection of endometrial cancer in women with postmenopausal bleeding: Systematic review and meta-analysis. *Gynecol Oncol* 2020; 157(3): 624-33.
- Muzaffar M, Akhtar KA, Yasmin S, Mahmood Ur R, Iqbal W, Khan MA. Menstrual irregularities with excessive blood loss: a clinico-pathological correlation. *J Pak Med Assoc.* 2005;55(11):486-9.
- Yusuf NW. Dysfunctional uterine bleeding: a retrospective clinicomorphological study over two years. *Pakistan J Obstet Gynaecol* 1996; 9(1): 27-30.
- Brahmaiah J, Kuppareddy LS, Papireddygar VK, Begum CS. Histomorphological Spectrum of Endometrial Tissue in Abnormal Uterine Bleeding. 2022.
- Vijayaraghavan A Sr, Jadhav C, Pradeep B, Bindu H, Kumaran S. A Histopathological Study of Endometrial Biopsy Samples in Abnormal Uterine Bleeding. *Cureus* 2022; 14(11): 31264.
- Kafle N, Shaukin S, Kafle SU, Singh M, Parajuli SB. Histopathological pattern of endometrial biopsies in patients with abnormal uterine bleeding attending Birat medical college teaching hospital. *Birat J Health Sci* 2020; 5(2): 1035-9.